

surveillance purposes. However, because of the small number of influenza virus (H5N1) case-patients, our study was too underpowered to draw any firm conclusions; results should be interpreted cautiously. In a study of cases in Vietnam, 5 case-patients did not have any identified exposure ≤ 7 days of illness onset (10). In China, the exposure period for surveillance of suspected cases now includes exposure to a wet poultry market ≤ 14 days before illness onset. Although data on person-to-person virus transmission are limited, close contacts of patients infected with influenza virus (H5N1) in China are monitored daily for 10 days after the last known exposure. Further studies are needed to quantify the incubation period after exposure to sick or dead infected poultry, a wet poultry market, or to an influenza A virus (H5N1) case-patient and to investigate the basis for any differences.

Acknowledgments

We thank the Centers for Disease Control and Prevention of the Hunan, Anhui, Sichuan, Fujian, Guangdong, Hubei, Liaoning, Shanghai, Jiangxi, Guangxi, Zhejiang, Xinjiang, and Jiangsu Provinces and the local governments that assisted us in coordinating our field investigations, in data collection, and in logistical support. We also thank Ratana Somrongsong and Sopon Iamisirithaworn, for review of the manuscript.

**Yang Huai, Nijuan Xiang,
Lei Zhou, Luzhao Feng,
Zhibin Peng,
Robert S. Chapman,
Timothy M. Uyeki,
and Hongjie Yu**

Author affiliations: Chinese Center for Disease Control and Prevention, Beijing, People's Republic of China (Y. Huai, N. Xiang, L. Zhou, L. Feng, Z. Peng, H. Yu); Chulalongkorn University, Bangkok, Thailand (Y. Huai, R.S. Chapman); and Centers for Disease Control and Prevention, Atlanta, Georgia, USA (T.M. Uyeki)

DOI: 10.3201/eid1411.080509

References

1. Areechokchai D, Jiraphongsa C, Laosiritaworn Y, Hanshaworakul W, O'Reilly M; Centers for Disease Control and Prevention. Investigation of avian influenza (H5N1) outbreak in humans—Thailand, 2004. *MMWR Morb Mortal Wkly Rep.* 2006;55(Suppl 1):3–6.
2. Tran TH, Nguyen TL, Nguyen TD, Luong TS, Pham PM, Nguyen VC, et al. Avian influenza A (H5N1) in 10 patients in Vietnam. *N Engl J Med.* 2004;350:1179–88. DOI: 10.1056/NEJMoa040419
3. Oner AF, Bay A, Arslan S, Akdeniz H, Sahin HA, Cesur Y, et al. Avian influenza A (H5N1) infection in eastern Turkey in 2006. *N Engl J Med.* 2006;355:2179–85. DOI: 10.1056/NEJMoa060601
4. Writing Committee of the Second World Health Organization. Consultation on clinical aspects of human infection with avian influenza A (H5N1). Update on avian influenza A (H5N1) virus infection in humans. *N Engl J Med.* 2008;358:261–73. DOI: 10.1056/NEJMra0707279
5. Ungechusak K, Auewarakul P, Dowell SF, Kitphati R, Auwanit W, Puthavathana P, et al. Probable person-to-person transmission of avian influenza A (H5N1). *N Engl J Med.* 2005;352:333–40.
6. Wang H, Feng ZJ, Shu YL, Yu HJ, Zhou L, Zu RQ, et al. Probable limited person-to-person transmission of highly pathogenic avian influenza A (H5N1) virus in China. *Lancet.* 2008;371:1427–34. DOI: 10.1016/S0140-6736(08)60493-6
7. Kandun IN, Wibisono H, Sedyaningsih ER, Yusharmen, Hadisoedarsuno W, Purba W, et al. Three Indonesian clusters of H5N1 virus infection in 2005. *N Engl J Med.* 2006;355:2186–94. DOI: 10.1056/NEJMoa060930
8. Yu HJ, Feng ZJ, Zhang XF, Xiang NJ, Huai Y, Zhou L, et al. Human influenza A (H5N1) cases, urban areas of People's Republic of China, 2005–2006. *Emerg Infect Dis.* 2007;13:1061–4.
9. World Health Organization. WHO case definitions for human infections with influenza A(H5N1) virus [cited 2008 July 20]. Available from http://www.who.int/csr/disease/avian_influenza/guidelines/case_definition2006_08_29/en/index.html
10. Dinh PN, Long HT, Tien NT, Hien NT, Mai le TQ, Phong le H, et al. Risk factors for human infection with avian influenza A H5N1, Vietnam, 2004. *Emerg Infect Dis* [serial on the Internet]. 2006 Dec [cited 2008 July 20]. Available from <http://www.cdc.gov/ncidod/EID/vol12no12/06-0829.htm>

Address for correspondence: Hongjie Yu, Office for Disease Control and Emergency Response, China CDC, 27 Nanwei Rd, Beijing 100050, People's Republic of China; email: yuhj@chinaacdc.cn

Mycobacterium haemophilum Infection after Alemtuzumab Treatment

To the Editor: The immunosuppressive agent alemtuzumab is a DNA-derived, humanized monoclonal antibody directed against the panlymphocyte, cell-surface antigen CD52 (1). The drug is approved for the treatment of refractory B-cell chronic lymphocytic leukemia (2) and also has been used after stem cell (3) and organ transplantations (4). Alemtuzumab causes profound and prolonged lymphocyte depletion, which results in a variety of complications involving infections (5). However, mycobacteria have rarely been reported to cause infection after alemtuzumab treatment. We describe infections with *Mycobacterium haemophilum*, a fastidious nontuberculous mycobacterium, in 2 patients who experienced cutaneous lesions while they received alemtuzumab.

Patient 1

A 65-year-old man with refractory chronic lymphocytic leukemia had been receiving treatment with alemtuzumab for 3 months. During a 5-week period beginning 15 weeks after the alemtuzumab therapy started, 20–30 tender nodular-ulcerative lesions developed on the patient's extremities. Most of the lesions were distributed along a saphenous vein site (Figure). Immediately before receiving

ing alemtuzumab, he had been given rituximab for 3 months. A punch biopsy of the cutaneous lesion showed lymphogranulomatous inflammation in the dermis. Acid-fast stains of the skin punch biopsy specimen, as well as aspirated material from the lesions, demonstrated acid-fast bacilli. Cultures on Middlebrook 7H11 agar (Becton Dickinson and Company, Sparks, MD, USA) containing X-factor strips incubated at 30°C showed growth of the acid-fast bacilli after 13 days. The isolate was subsequently identified as *M. haemophilum* by using conventional biochemical profiles and assessment of morphologic features, including an optimal growth temperature of 30°C and a hemin requirement. The patient was treated with 4 drugs (rifampin, doxycycline, clarithromycin, ciprofloxacin), and he rapidly improved. Susceptibility testing, using broth MIC determinations described in Clinical and Laboratory Standards Institute publication M-24A (www.clsi.org/source/orders/free/m24-aa.pdf), indicated that the isolate was sensitive to clarithromycin, ciprofloxacin, clofazimine, and linezolid; intermediately sensitive to rifampin; but resistant to rifabutin, doxycycline, ethambutol, streptomycin, and amikacin. The antimicrobial drugs the patient was receiving were changed to only rifampin, clarithromycin, and ciprofloxacin. He completed a 6-month course of treatment without recurrence of the lesions.

Patient 2

A 17-year-old woman with severe systemic lupus erythematosus and secondary myelodysplastic syndrome received an unrelated T-cell depleted bone marrow transplant. Her conditioning regimen included melphalan, thiotepa, fludarabine, and 2 doses of alemtuzumab. She initially did well posttransplant and was discharged from the hospital. Approximately 3 months later, 40–50 tender erythematous papular lesions developed on her

extremities. A skin biopsy specimen showed mycobacterial panniculitis. Cultures from skin, blood, and bone marrow grew *M. haemophilum* after 18–19 days' incubation. She was successfully treated with rifampin, clarithromycin, and gatifloxacin; however, she died several months later from unrelated complications.

M. haemophilum was first described in 1978 when it was isolated from cutaneous lesions of a woman from Israel with Hodgkin disease (6). *M. haemophilum* most often causes joint, cutaneous, and pulmonary infections in immunocompromised patients (7) and lymphadenitis in immunocompetent children (8). *M. haemophilum* is a fastidious organism that requires media supplemented with ferric ions in the form of hemin, hemoglobin, or ferric ammonium citrate, and incubation at 30°C–32°C for several weeks. On the basis of our experience at Memorial Sloan-Kettering Cancer Center (23 cases of *M. haemophilum* infection observed from 1990 through 2000) (9), the fol-

lowing specimens are routinely set up for culture: blood smear specimens that are positive for acid-fast bacilli, synovial or joint fluids, skin biopsy specimens, cutaneous lesions, ulcers, abscesses, lymph nodes, and lung biopsy specimens. Culture media include Middlebrook 7H11 agar plates with a hemin-containing paper strip (X-factor) placed on the agar surface that are then incubated at 30°C for 6 weeks. Growth of the organism is usually detected within 2 to 3 weeks, and the isolates are usually susceptible in vitro to the quinolones, macrolides, and rifamycins and resistant to several drugs for tuberculosis, including ethambutol, isoniazid, and pyrazinamide (9).

Alemtuzumab has been associated with the development of infections caused by a variety of microorganisms. However, mycobacteria have infrequently been the reported cause. In a review of 547 organ transplant recipients who received alemtuzumab treatment, miliary tuberculosis developed in 1 recipient of a kidney trans-

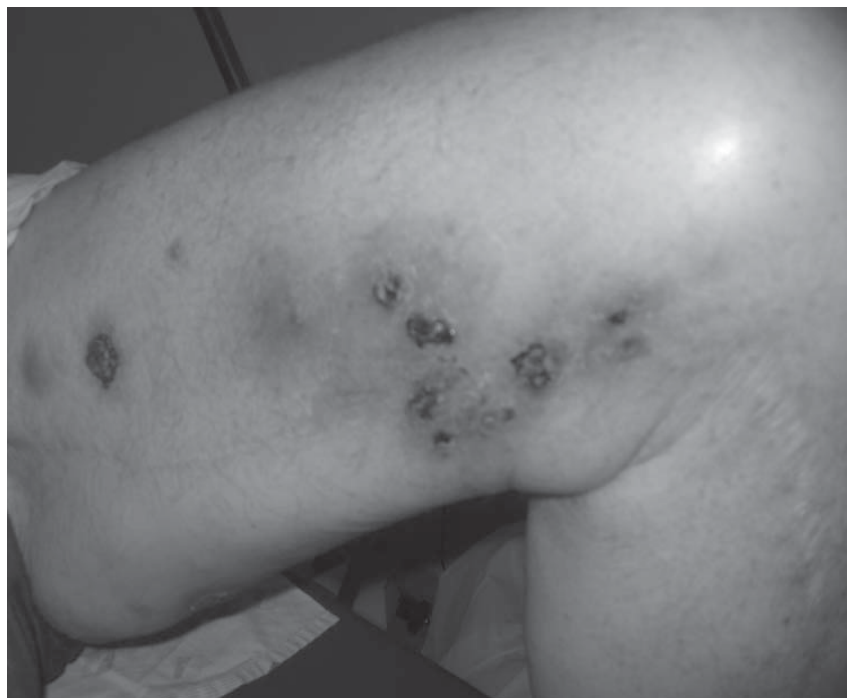


Figure. Nodular-ulcerative skin lesions on the left thigh caused by *Mycobacterium haemophilum* infection in a patient with chronic lymphocytic leukemia (patient 1) whose condition had been treated with alemtuzumab.

plant, and pulmonary infection with *M. kansasii* developed in 2 recipients of lung transplants (5). There is also a case report of systemic *M. bovis* infection developing in a patient with relapsing B chronic lymphocytic leukemia after administration of alemtuzumab (10).

Although we believe that alemtuzumab is responsible for the severe immunosuppression that predisposed these patients to *M. haemophilum* infection, other explanations are plausible. For example, patient 1 had received rituximab and cyclophosphamide for 6 months. These drugs, in addition to his underlying disease of chronic lymphocytic leukemia, may have predisposed him to *M. haemophilum* infection. However, his lesions did not appear until he received alemtuzumab. In patient 2, the immunosuppression associated with his transplant may have predisposed the patient to *M. haemophilum* infection.

This report identifies *M. haemophilum* as an opportunistic pathogen in patients who have received alemtuzumab. We recommend that all patients who have received at least 1 dose of alemtuzumab, and who have undiagnosed tender skin lesions located over the extremities, be evaluated by using appropriate techniques to isolate *M. haemophilum*. Communication with microbiology laboratory staff concerning appropriate methods for detection of the organism is crucial.

**Mini Kamboj, Eddie Louie,
Timothy Keihn,
Genovefa Papanicolaou,
Michael Glickman,
and Kent Sepkowitz**

Author affiliations: Memorial Sloan-Kettering Cancer Center, New York, New York, USA (M. Kamboj, T. Keihn, G. Papanicolaou, M. Glickman, K. Sepkowitz); and New York University, New York (E. Louie)

DOI: 10.3201/eid1411.071321

References

1. Ferrajoli A, O'Brien S, Keating MJ. Alemtuzumab: a novel monoclonal antibody. *Expert Opin Biol Ther.* 2001;1:1059–65. DOI: 10.1517/14712598.1.6.1059
2. Keating MJ, Flinn I, Jain V, Binet JL, Hillmen P, Byrd J, et al. Therapeutic role of alemtuzumab (Campath-1H) in patients who have failed fludarabine: results of a large international study. *Blood.* 2002;99:3554–61. DOI: 10.1182/blood.V99.10.3554
3. Ho AY, Pagliuca A, Kenyon M, Parker JE, Mijovic A, Devereux S, et al. Reduced-intensity allogeneic hematopoietic stem cell transplantation for myelodysplastic syndrome and acute myeloid leukemia with multilineage dysplasia using fludarabine, busulfan, and alemtuzumab (FBC) conditioning. *Blood.* 2004;104:1616–23. DOI: 10.1182/blood-2003-12-4207
4. Shapiro R, Ellis D, Tan HP, Moritz ML, Basu A, Vats AN, et al. Antilymphoid antibody preconditioning and tacrolimus monotherapy for pediatric kidney transplantation. *J Pediatr.* 2006;148:813–8. DOI: 10.1016/j.jpeds.2006.01.008
5. Peleg AY, Husain S, Kwak EJ, Silveira FP, Ndirangu M, Tran J, et al. Opportunistic infections in 547 organ transplant recipients receiving alemtuzumab, a humanized monoclonal CD-52 antibody. *Clin Infect Dis.* 2007;44:204–12. DOI: 10.1086/510388
6. Sompolinsky D, Lagziel A, Naveh D, Yankilevitz T. *Mycobacterium haemophilum* sp. nov., a new pathogen of humans. *Int J Syst Bacteriol.* 1978;28:67–75.
7. Saubolle MA, Kiehn TE, White MH, Rudinsky MF, Armstrong D. *Mycobacterium haemophilum*: microbiology and expanding clinical and geographic spectra of disease in humans. *Clin Microbiol Rev.* 1996;9:435–47.
8. Bruijnesteijn van Coppenraet LE, Kuijper EJ, Lindeboom JA, Prins JM, Class EC. *Mycobacterium haemophilum* and lymphadenitis in children. *Emerg Infect Dis.* 2005;11:62–8.
9. Shah MK, Sebti A, Kiehn TE, Massarella SA, Sepkowitz KA. *Mycobacterium haemophilum* in immunocompromised patients. *Clin Infect Dis.* 2001;33:330–7. DOI: 10.1086/321894
10. Abad S, Gyan E, Moachon L, Bouscary D, Sicard D, Dreyfus F, et al. Tuberculosis due to *Mycobacterium bovis* after alemtuzumab administration. *Clin Infect Dis.* 2003;37:e27–8. DOI: 10.1086/375690

Address for correspondence: Mini Kamboj, Department of Medicine, Memorial Sloan-Kettering Cancer Centers, 1275 York Ave, Box 9, New York, NY 10021, USA; email: kambojm@mskcc.org

Prior Evidence of Putative Novel Rhinovirus Species, Australia

To the Editor: Briese et al. (1) are to be congratulated for their delineation of the global geographic presence of human rhinovirus (HRV) strains similar to those reported in 2006 from one third of cases of an otherwise pathogen-negative respiratory outbreak in New York. Of equal importance is the temporal occurrence of these strains. Although it is intriguing to suggest, on the basis of limited sequence data, that these strains were circulating at least 2 centuries earlier (1), Briese et al. neglect to acknowledge empirical evidence that what we now call HRV-C strains circulated before 2004–2005. Unculturable PCR-positive rhinoviruses were reported in 1993; however, more compelling is the fact that subgenomic sequence and phylogenetic data were reported from Belgium (2), Australia (3), and then New York (4). The Belgium noncoding sequences were reported in 2006 but originated from specimens collected in 1998–1999. Australian coding sequences from 2003 to 2004 were assigned, for the first time, to a novel clade called HRV-A2, reflecting both their phylogenetic isolation and branching from the known HRV-A strains (3).

It can be deduced that NY-041 and NY-060, strains from the 2004 New York winter outbreak, are variants (>98% amino acid identity) of the first characterized HRV-A2 strain, HRV-QPM (4,5). More recently, we proposed that the HRV-A2 strains diverged sufficiently to meet several of the International Committee on Taxonomy of Viruses criteria for classifying a putative new species, HRV-C (6).

It is an exciting time for those interested in rhinoviruses. With increased implementation of multiplexed screening approaches (such as the MassTag PCR), or by simply including a specific