

4. Pavan WO. Chikungunya - Italy (Emilia Romagna): confirmed. ProMed. 2007 Sep 3 [cited 2008 Mar 17]. Available from <http://www.promedmail.org>, archive no. 20070903.2899.
5. Pfeffer M, Linssen B, Parke MD, Kinney RM. Specific detection of chikungunya virus using a RT-PCR/nested PCR combination. *J Vet Med B Infect Dis Vet Public Health*. 2002;49:49–54.
6. Pastorino B, Bessaud M, Grandadam M, Murri S, Tolou HJ, Peyrefitte CN. Development of a TaqMan RT-PCR assay without RNA extraction step for the detection and quantification of African chikungunya viruses. *J Virol Methods*. 2005;124:65–71.
7. Beltrame A, Angheben A, Bisoffi Z, Monteiro G, Marocco S, Calleri G, et al. Imported chikungunya infection, Italy [letter]. *Emerg Infect Dis* [serial on the Internet]. 2007 Aug [cited 2008 Mar 17]. Available from <http://www.cdc.gov/EID/content/13/8/1264.htm>
8. Romi R. *Aedes albopictus* in Italy: an underestimated health problem. *Ann Ist Super Sanita*. 2001;37:241–7.

Address for correspondence: Paolo Bonilauri, Istituto Zooprofilattico della Lombardia e dell' Emilia Romagna, Sezione Diagnostica di Reggio Emilia via Pitagora, 2 Reggio Emilia, Reggio Emilia 42100 Italy; email: paolo.bonilauri@bs.izs.it

Persistent Human Metapneumovirus Infection in Immunocompromised Child

To the Editor: Respiratory viral infections can be associated with a wide range of clinical manifestations from self-limiting upper respiratory tract diseases to pneumonia (1). However, in general, respiratory viral infections are more likely to progress to more severe diseases in immunocompromised patients. Human metapneumovirus (hMPV) has been reported in most parts of the world as a cause of acute respiratory tract in-

fections in persons of all age groups (2). Fatal hMPV infections have been reported in immunocompromised patients, including a 17-month-old girl who had acute lymphoblastic leukemia (3) and a 33-year-old woman who had received a hematopoietic stem cell transplant (HSCT) (4). In adult HSCT recipients, fatal pneumonia (5) and persistent hMPV infection without respiratory symptoms have been described (6). In addition, adult lung transplant recipients have been able to clear hMPV infection despite high levels of immunosuppression (7). We report a case of persistent hMPV infection in a child with severe combined immunodeficiency disorder (SCID) who shed hMPV during an 11-month period.

The child, a girl who was born in January 2002, received an allogeneic haploidentical stem cell transplant from her father in May 2002 after her diagnosis of SCID. Infection with influenza A virus (H3N2) was diagnosed on April 2005 and progressed to a chronic pneumonitis of the lingua. She received successive courses of anti-influenza agents (amantadine, oseltamivir, and zanamivir) for 1 year during which time several positive influenza cultures were obtained (8). Four years after the transplant, she was still lymphopenic ($800 \times 10^9/L$, mostly T cells) and had chronic graft-versus-host disease, which had been treated with steroids (prednisone 2.5 mg twice a day for many months). She also had a mild chronic cough but did not need supplemental oxygen while she was receiving nebulized zanamivir (10–20 mg twice a day). Her 2 nasopharyngeal aspirate (NPA) specimens from June and July 2006 were negative for influenza virus. However, positive cultures for hMPV were obtained from NPA and bronchoalveolar lavage specimens collected on July 2006. After receiving this result, we performed retrospective and prospective molecular detection studies for hMPV for this patient. HMPV was de-

tected by reverse transcription-PCR for the F and G genes (9) in 6 and 7 NPA samples, respectively, collected during an 11-month period from November 4, 2005, through October 4, 2006. These samples were obtained for surveillance of influenza infection in this child with persistent cough.

Amplified hMPV G sequences were aligned by using the Clustal W program (www.molecularrevolution.org/cdc/software/clustalw). A phylogenetic tree was constructed with MEGA 3.1 software (www.megasoftware.net) by using the neighbor-joining algorithm with Kimura-2 parameters. Sequence analysis of the hMPV G gene showed that all strains belonged to the B2 genotype, which clustered with hMPV Can98–75 and NL1/94 reference strains (Figure, panel A). Amplified hMPV G gene sequences of the 6 samples collected in 2006 were identical, but they had 96.7% and 92.8% nucleotide and amino acid identities, respectively, with the initial strain from November 2005, which clearly indicates 2 viral strains (Figure, panel B). Similar results were obtained with the F gene (data not shown). Inoculation of the respiratory samples on a panel of 10 cell lines as previously described (10) showed that only 2 of 7 NPA samples were positive for hMPV by culture; 2 of the 5 remaining samples were positive for influenza A, which may have masked the cytopathic effects of hMPV on rhesus monkey kidney (LLC-MK2) cells.

Persistent hMPV infection in asymptomatic adult HSCT recipients has been described (6). In that study, hMPV was isolated from 2 patients in 2 consecutive samples collected 12–56 days apart. However, virus evolution was not adequately investigated because it was based on sequence analysis of a 150-bp fragment from the highly conserved nucleoprotein gene (6). Unlike in previous reports (6,7), characterization of hMPV strains in our study was performed by sequence

analysis of a 633-bp fragment from the most variable hMPV G gene. Our findings showed 2 distinct hMPV variants of the same genotype (B2). These variants might represent a viral drift after immune pressure but most likely

was the result of 2 different infections in the immunocompromised child. The latter hypothesis is suggested by the considerable amino acid variability (15 aa differences in the 211-aa region of the G protein) between strains col-

lected on November, 4, 2005, and January, 20, 2006, compared with identical sequences for the strains recovered over the next 10 months. Debiaggi et al. (6) previously suggested that persistent hMPV infection in HSCT patients was attributable to their inability to clear the virus because of impaired immune response. By contrast, adult lung transplant recipients were found to be able to achieve hMPV clearance despite their severe immunosuppression status (7). Because both fatal and mild or asymptomatic hMPV infections have been reported in immunocompromised hosts, additional studies are needed to determine whether such differing outcomes are due to viral, host, or environmental factors. In conclusion, this case of persistent hMPV infection associated with relatively mild respiratory symptoms in an immunocompromised child suggests that the host's immune response may play a key role in disease pathogenesis.

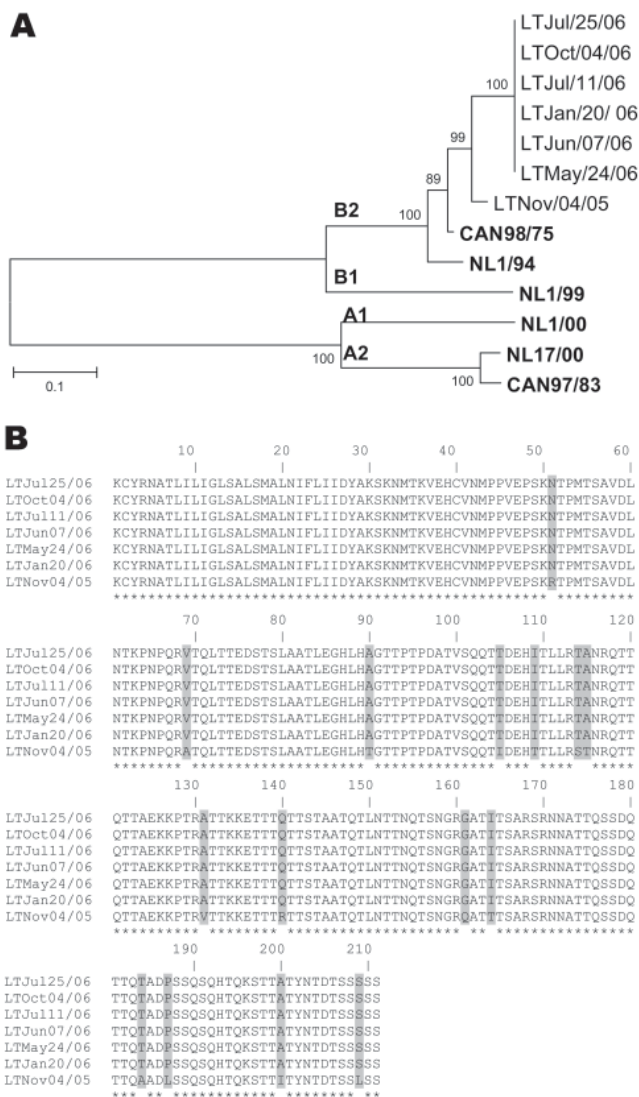


Figure. A) Phylogenetic analysis of human metapneumovirus (hMPV) strains isolated during an 11-month period based on nucleotide sequences of the G gene. Multiple nucleotide sequence alignments were performed by using the ClustalW program (www.molecularevolution.org/cdc/software/clustalw); a phylogenetic tree was constructed with MEGA 3.1 software (www.megasoftware.net) by using the neighbor-joining algorithm with Kimura-2 parameters. The analysis included the following hMPV reference strains: Can98/75 (GenBank accession no. AY485245), NL1/94 (AY304362), NL1/99 (AY304361), NL1/00 (AF371337), NL17/00 (AY304360), and Can97/83 (AY485253). Scale bar indicates 1 substitution for every 10 nucleic acid residues. **Boldface** indicates reference isolates. B) Comparison of the partial amino acid sequences (residues 26–236) of the G protein of hMPV isolates recovered during an 11-month period from an immunocompromised child. Asterisks denote identical residues; shaded boxes highlight different amino acids between the hMPV variant of November 4, 2005, and the subsequent variants from January 20, 2006, to October 4, 2006.

Yacine Abed*†
and Guy Boivin*†

*Centre Hospitalier Universitaire de Québec, Québec City, Québec, Canada; and †Infectious Disease Research Centre, Québec City, Québec, Canada

References

1. Abed Y, Boivin G. Treatment of respiratory viral infections. *Antiviral Res.* 2006;70:1–16.
2. Hamelin ME, Abed Y, Boivin G. Human metapneumovirus: a new player among respiratory viruses. *Clin Infect Dis.* 2004;38:983–90.
3. Pelletier G, Déry P, Abed Y, Boivin G. Respiratory tract reinfections by the new human *Metapneumovirus* in an immunocompromised child. *Emerg Infect Dis.* 2002;8:976–8.
4. Cane PA, van den Hoogen BG, Chakrabarti S, Fegan CD, Osterhaus AD. Human metapneumovirus in a hematopoietic stem cell transplant recipient with fatal lower respiratory tract disease. *Bone Marrow Transplant.* 2003;31:309–10.
5. Englund JA, Boeckh M, Kuypers J, Nichols WG, Hackman RC, Morrow RA, et al. Fatal human metapneumovirus infection in stem-cell transplant recipients. *Ann Intern Med.* 2006;144:344–9.

6. Debiaggi M, Canducci F, Sampaolo M, Marinozzi MC, Parea M, Terulla C, et al. Persistent symptomless human metapneumovirus infection in hematopoietic stem cell transplant recipients. *J Infect Dis.* 2006;194:474–8.
7. Larcher C, Geltner C, Fischer H, Nachbaur D, Muller LC, Huemer HP. Human metapneumovirus infection in lung transplant recipients: clinical presentation and epidemiology. *J Heart Lung Transplant.* 2005;24:1891–901.
8. Baz M, Abed Y, McDonald J, Boivin G. Characterization of multidrug-resistant influenza A/H3N2 viruses shed during one year by an immunocompromised child. *Clin Infect Dis.* 2006;43:1555–61.
9. Ludewick HP, Abed Y, Van Niekerk N, Boivin G, Klugman KP, Madhi SA. Human metapneumovirus genetic variability, South Africa. *Emerg Infect Dis.* 2005;11:1074–8.
10. Boivin G, Abed Y, Pelletier G, Ruel L, Moison D, Côté S, et al. Virological features and clinical manifestations associated with human metapneumovirus: a new paramyxovirus responsible for acute respiratory-tract infections in all age groups. *J Infect Dis.* 2002;186:1330–4.

Address for correspondence: Guy Boivin, Research Center in Infectious Diseases, Centre Hospitalier Universitaire de Québec—Centre Hospitalier Université Laval, Rm RC-709, 2705 Laurier Blvd, Quebec City, QC, Canada G1V 4G2; email: guy.boivin@crchul.ulaval.ca

Leptospirosis in Taiwan, 2001–2006

To the Editor: Leptospirosis is a zoonotic disease that has now been identified as an emerging infectious disease (1,2). It is caused by pathogenic spirochetes of the genus *Leptospira*. The natural hosts for *Leptospira* spp. come from a variety of species (2–4), of which the rodent is the most important reservoir (4,5). The incubation period range for leptospirosis is usually 5–14 days, with a range of 2–30 days (4). Leptospirosis is a disease of humid tropical and subtropical countries. Ac-

cording to the World Health Organization (4), probable leptospirosis incidence ranges from ≈ 0.1 –1 case/100,000 population/year in temperate climates to 10–100 cases/100,000 population/year in humid tropical climates. Leptospirosis epidemics are often related to heavy rainfall and flooding (1,6,7). Because of its climate, Taiwan may be at high risk for leptospirosis. We therefore investigated human leptospirosis in Taiwan and the relationship between leptospirosis incidence and rainfall pattern.

Taiwan is a medium-sized archipelago in East Asia; the Tropic of Cancer runs through its center. The northern part of Taiwan is subtropical; the southern part is tropical. Taiwan lies in the path of many tropical storms and typhoons that bring extremely heavy rainfall usually during July–September. The annual “plum rain” season in May and June also brings a lot of precipitation. Because of its tropical and subtropical marine climate, Taiwan enjoys rich agricultural productivity throughout the year, which is favorable for rodent infestations (8,9).

In Taiwan, reported cases of leptospirosis have been investigated by the Centers for Disease Control since 2001. Leptospirosis should be suspected in patients who have fever; headache; myalgia; abdominal pain; prostration; conjunctival suffusion; meningeal irritation and aseptic meningitis; anuria, oliguria, or proteinuria; jaundice; acute renal insufficiency; or gastrointestinal or lung hemorrhage. Patients with suspected leptospirosis are reported by physicians to Taiwan’s Centers for Disease Control through the Notifiable Disease Surveillance System, after which local health bureaus collect urine and blood samples for confirmation by serologic testing. Urine and blood samples from patients with clinically suspected leptospirosis are inoculated into Ellinghausen-McCullough-Johnson-Harris culture medium plus 5-fluorouracil and incubated at 30°C for 8–12 weeks.

Cultures are examined by dark-field microscopy every week. Alternatively, latex agglutination assay may be used for rapid serologic diagnosis of serum from patients with clinically suspected leptospirosis (10). Samples with positive latex agglutination assay results should be confirmed by microscopic agglutination test (MAT). An antibody titer ≥ 100 as determined by MAT is regarded as a probable case of leptospirosis. The local health bureau again collects patients’ serum during the convalescent phase of illness for confirmation by MAT. A laboratory-confirmed case is defined as the isolation of leptospires from urine and blood or a 4-fold increase in antibody titer between acute- and convalescent-phase samples.

During 2001–2006, of 7,733 suspected human cases of leptospirosis, 291 cases were confirmed. The major serotype identified was *L. santarosai* serovar Shermani. The mean annual incidence was 0.21 cases/100,000 population. The laboratory-confirmed cases were observed in Taiwan, mostly in male patients (83.5%) (Figure, panel A). Cases occurred in all age groups but were more common (90%) in those 25–74 years of age. Age-specific incidence was highest for persons 55–64 years of age; mean annual incidence was 0.57/100,000 population.

Rainfall data from the Central Weather Bureau of the Republic of China showed typically high rainfall (252–433 mm/month) in Taiwan during May–September. Heavy rains were followed by an increase in laboratory-confirmed cases of leptospirosis (Figure, panel B); June–October accounted for 60% of cases, with a higher incidence of 0.022–0.028 cases/100,000 population. In October–December, monthly rainfall was below average (201.1 mm/month), but leptospirosis incidence was above average (0.018/100,000). Specifically, 25 (74%) of leptospirosis cases in October, 10 (42%) in November, and 4 (19%) in December were likely as-