

and Federal University of Bahia, Salvador, Brazil (M.G. Teixeira)

DOI: 10.3201/eid1701.100321

***Apophysomyces variabilis* Infections in Humans**

To the Editor: The fungus *Apophysomyces elegans* (order Mucorales) is a thermotolerant species that causes severe infections among humans. In contrast to other fungi that cause zygomycosis, which have a worldwide distribution and are rarely found in immunocompetent hosts, *A. elegans* has been reported mainly in areas with warm climates as an emerging pathogen that causes mostly cutaneous infections after injury to the skin (1). This fungus was discovered in 1979 (2) and until recently was considered the only species in the genus.

A polyphasic study of clinical and environmental strains of *A. elegans*, including analysis of several genes, showed that the genus contained 4 well-characterized species (3). Of 16 isolates tested in this study, only 2 from soil in India were *A. elegans*. Most of the isolates were *A. variabilis*. The incidence of *A. variabilis* in humans is unknown and difficult to ascertain because most cases had isolates that were not properly preserved. These fungi usually cause necrotizing fasciitis, but rhino-orbito-cerebral or renal infections have also been reported (1). Whether these infections are produced by different *Apophysomyces* spp., have different responses to antifungal drugs, or have differences in virulence is unknown.

To assess incidence of *Apophysomyces* spp. in a tertiary hospital (Government Medical College Hospital, Chandigarh, India), which usually receives patients with zygomycosis, a retrospective study was conducted during November 2001–April 2009. Nine patients were identified as having primary cutaneous zygomycosis. For 4 patients, fungal isolates were morphologically identified as *A. elegans*. A description of clinical findings, their management, and outcomes for these

9 patients has been reported (4). The 4 isolates were sent to the Universitat Rovira i Virgili (Reus, Spain) for molecular analysis.

The internal transcribed spacer region of these isolates was sequenced and compared with those of type strains of *Apophysomyces* spp. Fungi were identified by morphologic (Figure, panel A) and molecular analysis as *A. variabilis* (99.6%–99.7% sequence identity with sequence of type strain CBS 658.93 [FN556436]). GenBank accession nos. of the 4 isolates are FN813491, FN813490, FN556442, and FN813492.

Another patient was also infected with *A. variabilis* fungi. The patient was a 45-year-old woman with diabetes from Derabassi (Punjab), India, who was hospitalized because of swelling in her right breast and blackening of overlying skin. A diagnosis of right breast gangrene was made. Therefore, local debridement of the swelling was conducted, and tissue samples were tested by microbiologic culture and histopathologic analysis.

A KOH wet mount showed broad aseptate hyphae with right-angled branching. The fungal isolate was tentatively identified as *A. elegans*. Histopathologic analysis confirmed a diagnosis of zygomycosis. The patient was treated under local anesthesia by debridement of infected tissue and some of the healthy surrounding tissue (Figure, panel B). However, an antifungal regimen could not be given because she had disturbed renal function. Her condition deteriorated, septicemia was observed, and she died from sudden cardiac arrest on the sixth day after admission. The fungal isolate was also identified as *A. variabilis* (98.9% identity, GenBank accession no. FN556443).

Although most cases of infection with *A. variabilis* fungi have been reported in India (5), infections with this fungus may have a wider distribution. A recent study demonstrated that this species represented 0.5% of fungi

References

- World Organization Health. Dengue and dengue haemorrhagic fever fact sheet 217. 2009 [cited 2010 Aug 10]. <http://www.who.int/mediacentre/factsheets/fs117/en/index.html>.
- Halstead SB. Dengue in the Americas and Southeast Asia: do they differ? *Rev Panam Salud Publica*. 2006;20:407–15. DOI: 10.1590/S1020-49892006001100007
- Siqueira JB Jr, Martelli CM, Coelho GE, Simplicio AC, Hatch DL. Dengue and dengue hemorrhagic fever, Brazil, 1981–2002. *Emerg Infect Dis*. 2005;11:48–53.
- Teixeira MG, Costa Mda C, Barreto F, Barreto ML. Dengue: twenty-five years since reemergence in Brazil. *Cad Saude Publica*. 2009;25(Suppl 1):S7–18. DOI: 10.1590/S0102-311X2009001300002
- Teixeira MG, Costa MC, Coelho GE, Barreto ML. Recent shift in age pattern of dengue hemorrhagic fever, Brazil. *Emerg Infect Dis*. 2008;14:1663. DOI: 10.3201/eid1410.071164
- Cavalcanti LP, Coelho IC, Vilar DC, Holanda SG, Escóssia KN, Souza-Santos R. Clinical and epidemiological characterization of dengue hemorrhagic fever cases in northeastern Brazil. *Rev Soc Bras Med Trop*. 2010;43:355–8.
- Vilar DC. Aspectos clínicos e epidemiológicos do dengue hemorrágico no Ceará, no período de 1994 a 2006. Dissertação (Mestrado). Ceará (Brazil): Escola Nacional de Saúde Pública; 2008 [cited 2010 Aug 10]. <http://bvsssp.icict.fiocruz.br/lilddbi/docsonline/4/3/1734-Vilardclfm.pdf>
- Brasil, Ministério da Saúde. Datasus [cited 2010 Aug 10]. <http://www2.datasus.gov.br/DATASUS/index.php?area=0206>
- Oliveira MF, Araújo JM, Ferreira OC Jr, Ferreira DF, Lima DB, Santos FB, et al. Two lineages of dengue virus type 2, Brazil. *Emerg Infect Dis*. 2010;16:576–8.
- Halstead SB. The Alexander D. Langmuir lecture. The pathogenesis of dengue. *Molecular epidemiology in infectious disease*. *Am J Epidemiol*. 1981;114:632–48.

Address for correspondence: Luciano P. Cavalcanti, Department of Community Health, School of Medicine, Federal University of Ceará, St. Prof. Costa Mendes 1608, 5th Floor, Fortaleza, CE 60430-140, Brazil; email: pamplona.luciano@gmail.com

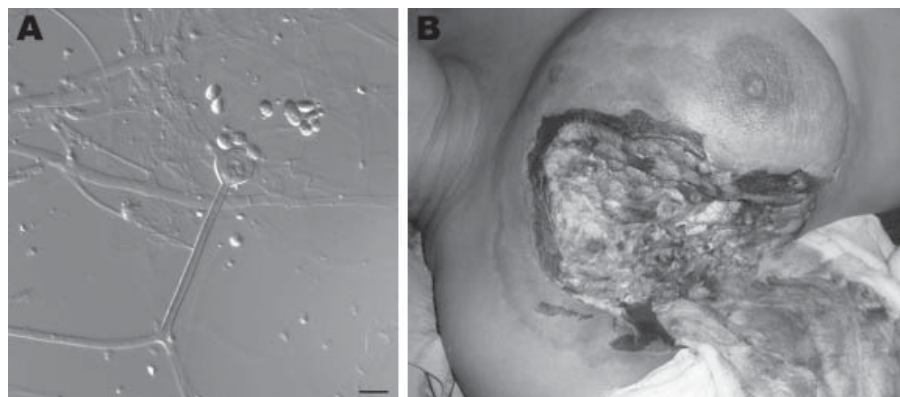


Figure. A) Sporangiophore (center) and sporangiospores of *Apophysomyces variabilis* fungi. Scale bar = 10 μ m. B) Clinical manifestations in a woman infected with *A. variabilis* fungi in the upper part of the chest and the breast. A color version of this figure is available online (www.cdc.gov/EID/content/17/1/134-F.htm).

of the order Mucorales isolated from clinical samples in the United States (6). Furthermore, a high mortality rate and the fact that most of these infections involve otherwise healthy patients make this a serious infection.

The number of infections with *Apophysomyces* spp. is underestimated because these fungi do not usually sporulate on standard fungal culture media used in clinical laboratories. These fungi require special nutrient-deficient growth medium (Czapek agar), a high temperature in comparison to other human pathogens (37°C–42°C), and prolonged incubation (7–10 days) (7).

A difference in mortality rate was observed when we compared patients in our study (80%) with those reported by Chakrabarti et al. (5) (28.5%) in India, even though treatment was generally similar, i.e., local débridement and amphotericin B. Other differences in our study were that the infection in 4 patients was preceded by intramuscular injection, and these 2 patients had diabetes mellitus.

In conclusion, *A. variabilis* is an emerging pathogenic fungus that can cause rapid and fatal infections in humans. As more isolates of *Apophysomyces* fungi become available, molecular typing studies must be conducted to better understand the epidemiology and distribution of different *Apophysomyces* spp.

**Josep Guarro,
Jagdish Chander,
Eduardo Alvarez,
Alberto M. Stchigel,
Kaushik Robin, Usha Dalal,
Hena Rani, Rajpal S. Punia,
and José F. Cano**

Author affiliations: Universitat Rovira i Virgili, Virgili, Reus, Spain (J. Guarro, E. Alvarez, A.M. Stchigel, J.F. Cano); and Government Medical College Hospital, Chandigarh, India (J. Chandler, K. Robin, U. Dalal, H. Rani, R.S. Puna)

DOI: 10.3201/eid1701.101139

References

1. Meis JF, Chakrabarti A. Changing epidemiology of an emerging infection: zygomycosis. *Clin Microbiol Infect*. 2009;15(Suppl 5):10–4. DOI: 10.1111/j.1469-0691.2009.02973.x
2. Misra PC, Srivastava KJ, Lata K. *Apophysomyces*, a new genus of the Mucorales. *Mycotaxon*. 1979;8:377–82.
3. Alvarez E, Stchigel AM, Cano J, Sutton DA, Fothergill AW, Chander J, et al. Molecular phylogenetic diversity of the emerging mucoralean fungus *Apophysomyces*: proposal of three new species. *Rev Iberoam Micol*. 2010;27:80–9. DOI: 10.1016/j.riam.2010.01.006
4. Chander J, Kaur J, Attri A, Mohan H. Primary cutaneous zygomycosis from a tertiary care centre in north-west India. *Indian J Med Res*. 2010;131:765–70.
5. Chakrabarti A, Ghosh A, Prasad GS, David JK, Gupta S, Das A, et al. *Apophysomyces elegans*: an emerging zygomycete in India. *J Clin Microbiol*. 2003;41:783–8. DOI: 10.1128/JCM.41.2.783-788.2003

6. Alvarez E, Sutton DA, Cano J, Fothergill AW, Stchigel A, Rinaldi MG, et al. Spectrum of zygomycete species identified in clinically significant specimens in the United States. *J Clin Microbiol*. 2009;47:1650–6. DOI: 10.1128/JCM.00036-09
7. Padhye AA, Ajello L. Simple method of inducing sporulation by *Apophysomyces elegans* and *Saksenaeva vasiformis*. *J Clin Microbiol*. 1988;26:1861–3.

Address for correspondence: José F. Cano, Unitat de Microbiologia, Facultat de Medicina i Ciències de la Salut, Institut d'Investigació Sanitària Pere i Virgili, Universitat Rovira i Virgili, C/Sant Llorenç 21, 43201 Reus, Tarragona, Spain; email: josep.cano@urv.cat

Letters

Letters commenting on recent articles as well as letters reporting cases, outbreaks, or original research are welcome. Letters commenting on articles should contain no more than 300 words and 5 references; they are more likely to be published if submitted within 4 weeks of the original article's publication. Letters reporting cases, outbreaks, or original research should contain no more than 800 words and 10 references. They may have 1 Figure or Table and should not be divided into sections. All letters should contain material not previously published and include a word count.