

This study was supported by the Hellenic Centre for Disease Control and Prevention.

**Anna Papa, Constantina Politis,  
Athina Tsoukala,  
Aikaterini Eglezou,  
Vassiliki Bakaloudi,  
Maria Hatzitaki,  
and Katerina Tsergouli**

Author affiliations: Aristotle University of Thessaloniki, Thessaloniki, Greece (A. Papa, K. Tsergouli); National Coordinating Haemovigilance Centre of the Hellenic Centre for Disease Control and Prevention, Athens, Greece (C. Politis); AHEPA University General Hospital Blood Centre, Thessaloniki (A. Tsoukala, V. Bakaloudi); Papanikolaou General Hospital Blood Bank, Thessaloniki (A. Eglezou); and Koutlibaneio General Hospital Blood Centre, Larissa, Greece (M. Hatzitaki)

DOI: <http://dx.doi.org/10.3201/eid1804.110771>

## References

- Centers for Disease Control and Prevention. Update: investigations of West Nile virus infections in recipients of organ transplantation and blood transfusion. *MMWR Morb Mortal Wkly Rep.* 2002;51:833–6.
- Papa A, Danis K, Baka A, Bakas A, Dougas G, Lytras T, et al. Ongoing outbreak of West Nile virus infections in humans in Greece, July–August 2010. *Euro Surveill.* 2010;15(34):pii:19644.
- Danis K, Papa A, Theocharopoulos G, Dougas G, Athanasiou M, Detsis M, et al. Outbreak of West Nile virus infection in Greece, 2010. *Emerg Infect Dis.* 2011;17:1868–72.
- Anastasiadou A, Economopoulou A, Kakoulidis I, Zilidou R, Butel D, Zorpidou D, et al. Non-neuroinvasive West Nile virus infections during the outbreak in Greece. *Clin Microbiol Infect.* 2011;17:1681–3. <http://dx.doi.org/10.1111/j.1469-0691.2011.03642.x>
- Papa A, Xanthopoulou K, Gewehr S, Mourelatos S. Detection of West Nile virus lineage 2 in mosquitoes during a human outbreak in Greece. *Clin Microbiol Infect.* 2011;17:1176–80. <http://dx.doi.org/10.1111/j.1469-0691.2010.03438.x>
- Papa A, Bakonyi T, Xanthopoulou K, Vazquez A, Tenorio A, Nowotny N. Genetic characterization of West Nile virus lineage 2, Greece, 2010. *Emerg Infect Dis.* 2011;17:920–2.
- Brault AC, Huang CY, Langevin SA, Kinney RM, Bowen RA, Ramey WN, et al. A single positively selected West Nile viral mutation confers increased virogenesis in American crows. *Nat Genet.* 2007;39:1162–6. <http://dx.doi.org/10.1038/ng2097>
- Kantzanou MN, Moschidis ZM, Kremastinou G, Levidiotou S, Karafoulidou A, Politis C, et al. Searching for West Nile virus (WNV) in Greece. *Transfus Med.* 2010;20:113–7. <http://dx.doi.org/10.1111/j.1365-3148.2009.00964.x>
- Sánchez-Seco MP, Rosario D, Domingo C, Hernandez L, Valdes K, Guzman MG, et al. Generic RT-nested-PCR for detection of flaviviruses using degenerated primers and internal control followed by sequencing for specific identification. *J Virol Methods.* 2005;126:101–9. <http://dx.doi.org/10.1016/j.jviromet.2005.01.025>
- Shi PY, Kauffman EB, Ren P, Felton A, Tai JH, Dupuis AP II, et al. High-throughput detection of West Nile virus RNA. *J Clin Microbiol.* 2001;39:1264–71. <http://dx.doi.org/10.1128/JCM.39.4.1264-1271.2001>

Address for correspondence: Anna Papa, First Department of Microbiology, Medical School, Aristotle University of Thessaloniki, 54124, Thessaloniki, Greece; email: [annap@med.auth.gr](mailto:annap@med.auth.gr)

## Tuberculosis Screening before Anti-Hepatitis C Virus Therapy in Prisons

**To the Editor:** Prisons represent a crucial setting for tuberculosis (TB) control. Worldwide, reported TB rates for correctional system populations have been 10–100× higher than rates for the local civilian populations, and TB outbreaks with a high number of TB multidrug-resistant cases have been documented (1,2). Prisons are known as social and sanitary pathology reservoirs in which TB is often associated with chronic

infectious diseases caused by HIV, hepatitis B virus (HBV), or hepatitis C virus (HCV) (2).

HCV prevalence among inmates is 30%–40% (range 2%–58%), which is higher than that in the general population and is related to injection drug use (3). For these reasons, effective anti-HCV therapeutic approaches are recommended by national and international guidelines for decreasing illness, death rates, and reservoirs of infection in prisons (4,5).

The standard of care for patients with chronic hepatitis C infection is represented by pegylated interferon- $\alpha$  (Peg-IFN) and ribavirin. These drugs determine complex antiviral, immunomodulatory, and antiproliferative actions, which can cause serious side effects such as leukopenia/neutropenia and alterations in the cytokine network (3). Although severe cellular immunodeficiency can often facilitate the development of many infections, only 4 clinical cases of TB in patients undergoing HCV antiviral therapy have been described in the literature (6–8), and only 1 of these was clearly described as a TB reactivation (7).

We describe a case of pulmonary TB reactivation during therapy with Peg-IFN and ribavirin in a 44-year-old white male inmate, affected by genotype 1b/4a chronic hepatitis C. After prison admission in 2009, he underwent routine screening tests for infectious diseases, which indicated HCV antibody, HBV surface antibody, HBV core IgG antibody, and tuberculin skin test positivity. Results of chest radiograph and HIV screening were negative.

His previous history involved injection drug use, smoking, and alcohol consumption. Anti-HCV therapy of directly observed administration of Peg-IFN  $\alpha$ -2a (180  $\mu$ g/wk) and ribavirin (1,200 mg/d) was started. During therapy, the patient had only mild musculoskeletal pain and temporary

irritability. During the 12th week of treatment, HCV-RNA decreased by  $1 \log_{10}$ ; therefore, the ribavirin dose was increased to 1,600 mg per day. Even after the therapy modification, no virologic suppression was found. Although during the 33rd week of therapy the patient had weakness, cough, and 2 episodes of hemoptysis, the results of a physical examination were unremarkable. Therapy was immediately discontinued. Sputum specimens collected on 3 consecutive days were positive for acid-fast bacilli. Nucleic acid amplification assays and cultures performed on mycobacteria growth indicator tube (Bactec MGIT; Becton Dickinson, Franklin Lakes, NJ, USA) and on Lowenstein-Jensen medium were positive for *Mycobacterium tuberculosis* isolates that later showed sensitivity to streptomycin, isoniazid, rifampin, and ethambutol.

The patient was isolated at the Institute of Respiratory Diseases, University of Sassari—Faculty of

Medicine, Sassari, Italy. A chest radiograph showed opacity in the upper right lung, and a high-resolution computed tomography scan (Figure) showed multiple lesions that were considered compatible with TB. CD4+ cell count (52.4%; 669 cells/mm<sup>3</sup>) was within reference range.

TB treatment with rifampin, isoniazid, pyrazinamide, and ethambutol with pyridoxine was started. After 4 weeks of therapy, 3 sputum specimens were negative for acid-fast bacilli, but a bacterial culture was still positive; mycobacteria indicator growth tube culture was negative after 5 weeks.

The interaction process between the IFN- $\alpha/\beta$  system and *M. tuberculosis* is not well known; nevertheless, Peg-IFN, alone and in combination with ribavirin, is considered potentially immunosuppressive (4,9). Immunodeficiency caused by Peg-IFNs and ribavirin may cause lower leukopenia/lymphopenia values than expected during anti-HCV treatment and may

also lower CD4+ cell count and function (10).

In the patient reported here, CD4+ cell count was within the reference range, and lung TB with excavations developed after 34 weeks of therapy. Before TB diagnosis, the patient had not shown any signs or symptoms of other infections and had not mentioned serious adverse effects from Peg-IFN and ribavirin treatment. However, the initial symptoms of TB and the common side effects of Peg-IFN therapy can be similar, which could have led to a delay in the diagnosis of TB.

In conclusion, even if only a few cases of active TB have been reported in the literature, it is well known that standard anti-HCV treatment increases the risk for infections. A high proportion of patients with positive purified protein derivative results, isolation of >30% of multidrug-resistant strains of *M. tuberculosis*, and high prevalence of HCV antibody are concomitant among inmates. These data, together with current recommendations for increasing use of Peg-IFN and ribavirin in marginalized populations in correctional facilities, show the need to consider TB risk before starting HCV antiviral therapy. The management of simultaneous HCV and *M. tuberculosis* infections in prisons presents particular difficulties and pitfalls to overcome. In prisons, the clinical history of inmates should be carefully evaluated, a tuberculin skin test or Quantiferon TB in Tube test (Cellestis, Melbourne, Australia) should be performed, and, if those results are positive, a chest radiograph should be taken. Before receiving Peg-IFN, purified protein derivative-positive patients should receive anti-TB chemoprophylaxis. The case described here underscores the need for a careful and multidisciplinary evaluation of inmate patients for latent TB before administration of Peg-IFN and ribavirin therapy, thus avoiding reactivation.

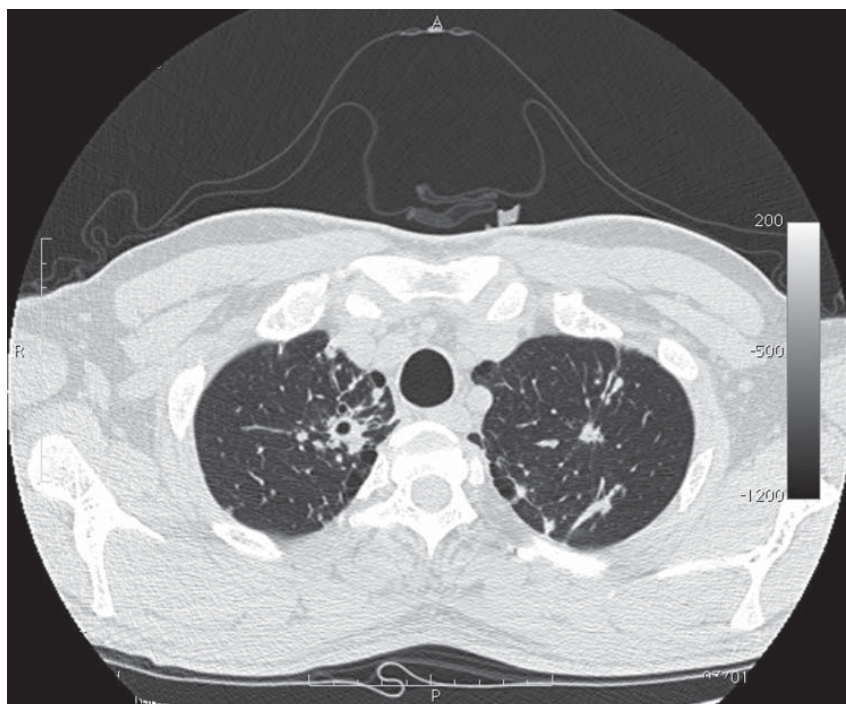


Figure. Computed tomography image of chest of patient with tuberculosis after anti-hepatitis C virus therapy. A parenchymal distortion 32 mm in diameter is shown in the upper right lung with initial central excavation 10 mm in diameter. Similar lesions 8 mm in diameter without central excavation are shown in the upper left lung.

**Sergio Babudieri,  
Andrea Soddu, Monica Murino,  
Paola Molicotti,  
Alberto A. Muredda,  
Giordano Madeddu,  
Alessandro G. Fois,  
Stefania Zanetti, Pietro Pirina,  
and Maria Stella Mura**

Author affiliations: University of Sassari, Sassari, Italy (S. Babudieri, A. Soddu, P. Molicotti, G. Madeddu, M.S. Mura, S. Zanetti, A.G. Fois, P. Pirina); and Ministry of Justice, Sassari (M. Murino, A.A. Muredda)

DOI: <http://dx.doi.org/10.3201/eid1804.111016>

## References

- World Health Organization. Tuberculosis control in prisons. A manual for programme managers. WHO/CDS/TB/2000.281. Geneva: The Organization; 2000 [cited 2012 Jan 31]. [http://whqlibdoc.who.int/hq/2000/WHO\\_CDS\\_TB\\_2000.281.pdf](http://whqlibdoc.who.int/hq/2000/WHO_CDS_TB_2000.281.pdf)
- Carbonara S, Babudieri S, Longo B, Starnini G, Monarca R, Brunetti B, et al. Correlates of *Mycobacterium tuberculosis* infection in a prison population. *Eur Respir J*. 2005;25:1070–6. <http://dx.doi.org/10.1183/09031936.05.00098104>
- Vescio MF, Longo B, Babudieri S, Starnini G, Rezza G, Monarca R. Correlates of HCV seropositivity in prison inmates: a meta-analysis. *J Epidemiol Community Health*. 2008;62:305–13. <http://dx.doi.org/10.1136/jech.2006.051599>
- National Institutes of Health. Consensus statement on management of hepatitis C. NIH Consens State Sci Statements. 2002;19:1–46 [cited 2012 Jan 31]. <http://consensus.nih.gov/2002/2002HepatitisC2002116html.htm>
- Almasio PL, Babudieri S, Barbarini G, Brunetto M, Conte D, Dentico P, et al. Recommendations for the prevention, diagnosis, and treatment of chronic hepatitis B and C in special population groups (migrants, intravenous drug users and prison inmates). *Dig Liver Dis*. 2011;43:589–95. <http://dx.doi.org/10.1016/j.dld.2010.12.004>
- Sabbatani S, Manfredi R, Marinacci G, Pavoni M, Cristoni L, Chiodo F. Reactivation of severe acute pulmonary tuberculosis during treatment with pegylated interferon-alpha and ribavirin for chronic HCV hepatitis. *Scand J Infect Dis*. 2006;38:205–8. <http://dx.doi.org/10.1080/00365540500263268>
- Belkahlia N, Kchir H, Maamouri N, Ouerghi H, Haritz FB, Chouaib S. Reactivation of tuberculosis during dual therapy with pegylated interferon and ribavirin for chronic hepatitis C [in French]. *Rev Med Interne*. 2010;31:e1–3. Epub 2010 Jun 3. <http://dx.doi.org/10.1016/j.revmed.2009.11.017>
- Farah R, Awad J. The association of interferon with the development of pulmonary tuberculosis. *Int J Clin Pharmacol Ther*. 2007;45:598–600.
- Puoti M, Babudieri S, Rezza G, Viale P, Antonini MG, Maida I, et al. Use of pegylated interferons is associated with an increased incidence of infections during combination treatment of chronic hepatitis C: a side effect of pegylation? *Antivir Ther*. 2004;9:627–30.
- Fried MW. Side effects of therapy of hepatitis C and their management. *Hepatology*. 2002;36(Suppl1):S237–44. <http://dx.doi.org/10.1002/hep.1840360730>

Address for correspondence Sergio Babudieri U.O. di Malattie Infettive Università degli Studi di Sassari via Enrico De Nicola n. 1 07100, Sassari, Italy; email: babuderi@uniss.it

## Deficient Reporting in Avian Influenza Surveillance, Mali

**To the Editor:** In response to influenza outbreaks caused by highly pathogenic avian influenza virus (HPAIV) throughout western Africa as of 2006, the National Veterinary Epidemiologic Surveillance Network of Mali (EPIVET-Mali) started conducting domestic and wild bird surveillance. No HPAI outbreaks were reported to the World Organisation for Animal Health. An evaluation survey conducted in 2009 enabled identification and correction of some weaknesses in the organization and functioning of the network (1). However, no attempt was made to assess how much information on bird health in backyard poultry farms (which account for ≈95% of the total

poultry population in Mali) actually reached EPIVET-Mali veterinarians and technicians. Therefore, we quantified reporting of clinical signs of avian diseases, especially those suggesting HPAI, by poultry owners in Mali.

We used a pilot-tested standardized quantitative and qualitative questionnaire to conduct face-to-face interviews in 32 randomly selected villages in the southern half of Mali (which accounts for 98% of the poultry population). In each village, we conducted interviews in 4 randomly chosen households. No eligibility criteria were used for household selection because all village households had poultry. Interviews were repeated 6 times (approximately every 3 months) during November 2009–February 2011 in the same villages and whenever possible in the same households. If it was not possible to repeat an interview in a previously interviewed household (absence of the household chief), the neighboring household was interviewed.

For each household, data were collected on number of sick and dead birds in the previous 3 months, clinical signs observed, and their notification or lack thereof to veterinary authorities. Households in which birds showed ≥3 of the following clinical signs (diarrhea, respiratory disorder, nervous signs, cyanosis of the combs or wattles, and mortality rate >50%) were considered as having clinical signs suggesting HPAI. The study was approved by the Direction Nationale des Services Vétérinaires and traditional authorities in all 32 villages, and oral consent was obtained from the poultry owners before interviews.

A total of 110–128 households were investigated at each study interval, depending on village accessibility and presence or absence of household chiefs (Table). We conducted 738 household investigations in 152 households (80 households were