

3. Musa OI, Aderibigbe SA, Salaudeen GA, Oluwole FA, Samuel SO. Community awareness of bird flu and the practice of backyard poultry in a north-central state of Nigeria. *J Prev Med Hyg.* 2010;51:146–51.
4. Pawitan JA. Averting avian influenza pandemic: SOS from a developing country. *Lancet Infect Dis.* 2006;6:756–7. [http://dx.doi.org/10.1016/S1473-3099\(06\)70638-7](http://dx.doi.org/10.1016/S1473-3099(06)70638-7)
5. Barennes H, Martinez-Aussel B, Vongphrachanh P, Strobe M. Avian influenza risk perceptions, Laos. *Emerg Infect Dis.* 2007;13:1126–8.
6. Fasina FO, Bisschop SP, Iboronke AA, Meseko CA. Avian influenza risk perception among poultry workers, Nigeria. *Emerg Infect Dis.* 2009;15:616–7. <http://dx.doi.org/10.3201/eid1504.070159>
7. Awan MA, Otte MJ, James AD. The epidemiology of Newcastle disease in rural poultry: a review. *Avian Pathol.* 1994;23:405–23. <http://dx.doi.org/10.1080/03079459408419012>
8. Kanamori S, Jimba M. Compensation for avian influenza cleanup. *Emerg Infect Dis.* 2007;13:341–2. <http://dx.doi.org/10.3201/eid1302.061391>
9. Desvaux S, Figuié M. Formal and informal surveillance systems: how to build bridges? [in French]. *Epidémiologie et Santé Animale.* 2011;59–60:352–5.

Address for correspondence: Sophie Molia, Centre de Coopération Internationale en Recherche Agronomique pour le Développement, Unité Propre de Recherche Animal et Gestion Intégrée des Risques, Campus International de Baillarguet, TA C-22/E, 34398 Montpellier Cedex 5, France; email: sophie.molia@cirad.fr

Letters

Letters commenting on recent articles as well as letters reporting cases, outbreaks, or original research are welcome. Letters commenting on articles should contain no more than 300 words and 5 references; they are more likely to be published if submitted within 4 weeks of the original article's publication. Letters reporting cases, outbreaks, or original research should contain no more than 800 words and 10 references. They may have 1 Figure or Table and should not be divided into sections. All letters should contain material not previously published and include a word count.

Myxozoan Parasite in Brain of Critically Endangered Frog

To the Editor: More than three quarters of critically endangered species of amphibians are threatened by infectious disease; several are already extinct (1). In 2010, the yellow-spotted bell frog (*Litoria castanea*), which was presumed to be extinct, was rediscovered in the Southern Tablelands of New South Wales, Australia. This species of frog had not been seen for 30 years, and a chytrid fungus, *Batrachochytrium dendrobatidis*, was thought to be the reason (1,2). The number of frogs in the rediscovered population is estimated to be 100; if numbers are that low, the yellow-spotted bell frog is the most critically endangered frog in Australia.

Several yellow-spotted bell frogs were collected for a captive breeding program at Taronga Zoo in Sydney, New South Wales, Australia. Generalized edema developed in a subadult male frog after 8 months of captivity in strict quarantine conditions. The frog subsequently died, and later an adult male frog was also found dead. Results of necropsy on both frogs at the Australian Registry of Wildlife Health revealed subcutaneous edema, intracoelomic fluid, and swollen kidneys with pale foci. Histopathologic examination demonstrated chronic severe tubulonephropathy and acute severe encephalomalacia. Coalescing foci of hemorrhage and malacia were observed in the caudal brainstem and were associated with small multinucleated ($1 \times 1 \mu\text{m}$) parasites forming plasmodia-like structures 10–20 μm in diameter (Figure). Plasmodia were present in large numbers (1–5/40 \times field) in the spinal cord. Organisms that were morphologically consistent with myxozoan parasites

detected in other frogs in Australia were found predominately within axons and were uncommonly present in vascular endothelial cells (3). Characteristic hepatic lesions, including lymphoplasmacytic hepatitis with biliary hyperplasia and loss of hepatocytes, were also present.

The cause of death was renal failure, a common problem in aged frogs; however, these frogs were young, and therefore the cause of the renal changes was perplexing. We considered whether toxins (e.g., improperly cured polyvinyl chloride glue) or an infectious process might be possible causes. Staff in the zoo's breeding program were questioned and indicated that the opportunity for introduction of a toxin was low. In addition, results for virus isolation and fungal and bacterial cultures were negative. We retrospectively reexamined histologic sections of an endangered booroolong frog (*Litoria booroolongensis*) that had similar brain lesions and intralesional myxozoan parasites (3). Tissue samples were submitted to the Faculty of Veterinary Science, The University of Sydney, for identification.

DNA was extracted from brain tissues (20 mg) by using the PureLink DNA Kit (Invitrogen, Mulgrave, Victoria, Australia). To test for myxozoans, we used a highly Myxozoa-specific PCR to amplify the complete internal transcribed spacer of the ribosomal DNA (3). Myxozoan-positive amplicons were directly sequenced at Macrogen Inc. (Seoul, South Korea), analyzed by using the CLC Main Workbench (CLC bio, Aarhus, Denmark), and deposited in GenBank (accession nos. JN977605–09).

PCR produced a 973-bp amplicon with DNA from brain and liver of the yellow-spotted bell frogs and the booroolong frog. DNA from the frogs showed 100% identity with each other, as did sequences from brain and liver. A BLASTN (4) search of

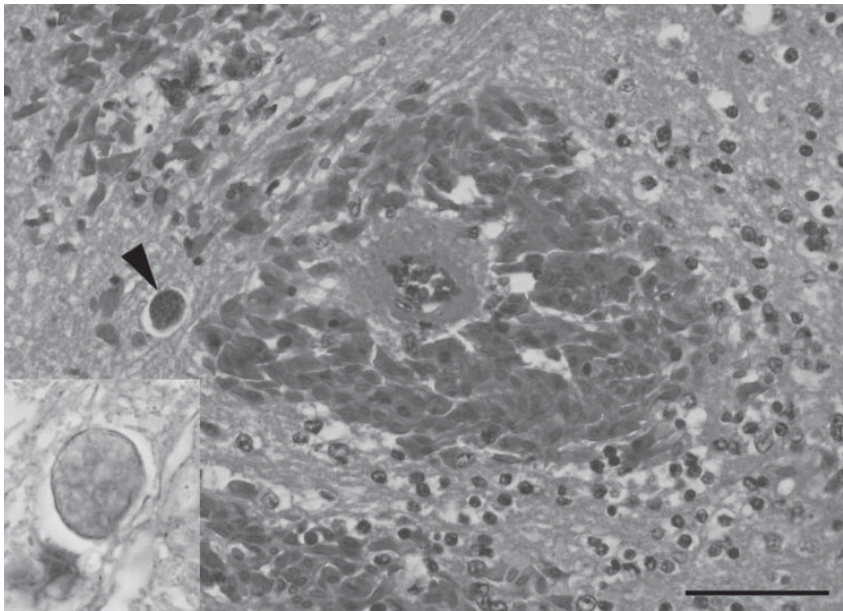


Figure. Acute severe encephalomalacia in the caudal brainstem of a captive yellow-spotted bell frog from Sydney, Australia. This lesion was characterized by hemorrhage, vascular necrosis, and parasites consistent with Myxozoa (arrowhead) (hematoxylin and eosin stain; scale bar = 50 μ m). Staining for axons confirmed intraaxonal location of the myxozoan parasites (inset, Holmes silver nitrate with Loxul Fast Blue stain).

public DNA sequence repositories returned the internal transcribed spacer of the ribosomal DNA of a myxozoan parasite, *Cystodiscus axonis* (syn. *Myxidium* sp. 'brain'), as the most closely related sequence (3,5). Pairwise comparison revealed 100% identity with *C. axonis*. During the brain phase of infection, *C. axonis* parasites reside within the myelinated axons (5), and special staining for axons confirmed this location for the brain parasites in this study. Screening of tissue sections from frogs trapped in the same locality as the yellow-spotted bell frogs revealed the presence of the parasite in the central nervous system of 8 of 10 stony creek frogs (*Litoria wilcoxi*) and 1 of 5 Eastern banjo frogs (*Limnodynastes dumerilii*).

Little information exists about the pathologic significance of myxozoan parasite in frogs and tadpoles (6). In Australia, *Cystodiscus* spp. parasites of frogs are emerging and have spread widely along the eastern coast in the past 40 years; they were first detected

in a frog collected in 1966 (7). Molecular characterization revealed 2 cryptic *Cystodiscus* parasites in frogs endemic to Australia and in the invasive cane toad (3). However, the cane toad did not introduce this parasite into Australia because cane toads from Hawaii, which are devoid of the parasite, were the source population for toads in Australia. The parasites seem to be native to Australia, and the invasive cane toad plays a spill-back role in their dissemination; however, it is not known how these parasites were disseminated outside the cane toad range (3).

Frog myxozoan parasites are yet to be documented as a cause of population decline; yet, the frequent presence of these parasites in moribund animals in captivity, including the yellow-spotted bell frog, demonstrates the need to monitor parasites in endangered frog populations worldwide. On the basis of our necropsy findings in the central nervous system of 2 yellow-spotted bell frogs, we encourage other

investigators to consider the potential role that myxozoan parasites may play in wild and captive populations of declining frogs worldwide.

Acknowledgment

The Australian Registry of Wildlife Health, Taronga Conservation Society Australia, acknowledges the Australian Biosecurity Intelligence Network for information management and communication systems that contributed to this research. The Network is a project of the National Collaborative Research Infrastructure Strategy.

This study was funded through the Faculty of Veterinary Science, University of Sydney, diagnostic laboratory.

**Ashlie Hartigan,
Cheryl Sangster, Carrie Rose,
David N. Phalen,
and Jan Šlapeta**

Author affiliations: The University of Sydney, Sydney, New South Wales, Australia (A. Hartigan, D. N. Phalen, J. Šlapeta); and Taronga Conservation Society Australia, Mosman, New South Wales, Australia (C. Sangster, K. Rose)

DOI: <http://dx.doi.org/10.3201/eid1804.111606>

References

1. Keesing F, Belden LK, Daszak P, Dobson A, Harvell CD, Holt RD, et al. Impacts of biodiversity on the emergence and transmission of infectious diseases. *Nature*. 2010;468:647–52. <http://dx.doi.org/10.1038/nature09575>
2. Mahony M. Review of the declines and disappearances within the bell frog species group (*Litoria aurea* species group) in Australia. In: Campbell A, editor. Declines and disappearances of Australian frogs. Canberra (Australia): Environment Australia; 1999. p. 81–93 [cited 2011 Nov 1]. <http://www.environment.gov.au/biodiversity/threatened/publications/pubs/frogs.pdf>
3. Hartigan A, Fiala I, Dyková I, Jirků M, Okimoto B, Rose K, et al. A suspected parasite spill-back of two novel *Myxidium* spp. (Myxosporaea) causing disease in Australian endemic frogs found in the invasive Cane Toad. *PLoS ONE*. 2011;6:e18871. <http://dx.doi.org/10.1371/journal.pone.0018871>

4. Zhang Z, Schwartz S, Wagner L, Miller W. A greedy algorithm for aligning DNA sequences. *J Comput Biol.* 2000;7:203–14. <http://dx.doi.org/10.1089/10665270050081478>
5. Hartigan A, Fiala I, Dyková I, Rose K, Phalen DN, Šlapeta J. New species of Myxosporea from frogs and resurrection of the genus *Cystodiscus* Lutz, 1889 for species with myxospores in gallbladders of amphibians. *Parasitology.* 2012; Epub ahead of print. <http://dx.doi.org/10.1017/S0031182011002149>
6. Sitjà-Bobadilla A. Can myxosporean parasites compromise fish and amphibian reproduction? *Proc Biol Sci.* 2009;276:2861–70. <http://dx.doi.org/10.1098/rspb.2009.0368>
7. Hartigan A, Phalen DN, Šlapeta J. Museum material reveals a frog parasite emergence after the invasion of the Cane Toad in Australia. *Parasit Vectors.* 2010;3:50. <http://dx.doi.org/10.1186/1756-3305-3-50>

Address for correspondence: Jan Šlapeta, Laboratory of Veterinary Parasitology, McMaster Building B14, Faculty of Veterinary Science, The University of Sydney, Sydney, New South Wales 2006, Australia; email: jan.slapeta@sydney.edu.au

Mayaro Virus Infection in Traveler Returning from Amazon Basin, Northern Peru

To the Editor: We report the case of a 27-year-old male Swiss tourist who spent 3.5 weeks (July 6–30, 2011) vacationing in the vicinity of Tarapoto, a small city located in the rainforests of the Amazon Basin in northern Peru. An acute febrile illness developed in the man during the second week of his stay. Signs and symptoms of illness were chills, malaise, frontal headache, generalized myalgia, a self-limiting painful cervical and inguinal lymphadenopathy (lasting ≈1 week), slowly progressive and pronounced

polyarthralgic pains of the peripheral joints, and a transient nonpruritic maculopapular rash (starting at the forearms ≈1 week after onset of fever and spreading to the trunk and later to the neck and face before fading after 3 days).

The traveler sought care at the local hospital, where physicians diagnosed suspected dengue fever on the basis of the clinical signs and symptoms, and received symptomatic treatment with paracetamol. The fever and other signs subsided within 1 week, except the arthralgia, which did not improve. The polyarthritis initially was accompanied by swelling of the affected joints and showed a symmetric pattern, mainly affecting the small joints of the hands and feet as well as the wrists, ankles, and knees.

After returning home to Switzerland, the patient consulted his general practitioner (August 1, 2011) because of persisting, incapacitating joint pains. The patient reported stiffness of the affected joints, mainly in the morning and after immobility. Physical examination of the affected joints did not reveal visible clinical signs of inflammation (swelling, redness, effusion). Laboratory tests were performed for complete blood count, liver and kidney function, C-reactive protein, and serologic testing for dengue virus, chikungunya virus, *Borrelia burgdorferi*, *Chlamydia trachomatis*, Epstein-Barr virus, parvovirus B19, *Salmonella* Typhi, and *S. Paratyphi*, but none revealed a cause for the symptoms. Over almost 2 more months, the joint pains did not improve; thus, the patient was referred to a rheumatologic clinic and subsequently to the Swiss Tropical and Public Health Institute, Basel, Switzerland, for evaluation of a putative travel-related cause of the polyarthralgia.

Because of the patient's travel history, the course of the illness and clinical signs and symptoms experienced during the journey, and

the evolution and characteristics of the persisting joint pains, we suspected an underlying Mayaro virus (MAYV) infection. Serologic testing (indirect immunofluorescence and virus neutralization assays) for several alphaviruses were performed as described (1), and the results (Table) confirmed our presumptive diagnosis.

Several viral infections (e.g., dengue, rubella, parvovirus B19, hepatitis B, hepatitis C, HIV, and human T-lymphotropic virus type 1) can be accompanied by arthralgia. However, the most prominent and long-lasting polyarthritic symptoms occur in patients infected by alphaviruses (family *Togaviridae*).

Alphaviruses are arthropod-borne viruses (arboviruses) that circulate among a wide variety of wild animals in relative mosquito vector-specific and host-specific enzootic cycles; infection in humans (dead-end hosts) is almost exclusively incidental. Clinical cases and virus isolation have been reported only from northern South America, where MAYV circulates in an enzootic sylvatic cycle (similar to that for yellow fever) involving forest-dwelling *Haemagogus* spp. mosquitoes as vectors and nonhuman primates as natural hosts (2). Infections in humans mostly occur sporadically, are strongly associated with occupational or recreational exposure in rainforest environments, and are assumed to represent spillover from the enzootic cycle (2).

MAYV was first isolated in Trinidad in 1954; since then, sporadic cases, clusters, outbreaks, and small epidemics of Mayaro fever have been reported from Brazil, Bolivia, Columbia, French Guiana, Guyana, Peru, Venezuela, and Surinam (3). In addition to the clinical cases and virus isolates reported from northern South America, serologic survey findings suggest the presence of MAYV in Costa Rica, Guatemala, and Panama (4) (online Appendix Figure, wwwnc.cdc).