

- unvaccinated dogs and in the endangered Simien jackal (*Canis simensis*) of Ethiopia. *Journal of Veterinary Medicine Series B*. 1992;39:233–5. <http://dx.doi.org/10.1111/j.1439-0450.1992.tb01162.x>
7. Zhang YZ, Fu ZF, Wang DM, Zhou JZ, Wang ZX, Lv TF, et al. Investigation of the role of healthy dogs as potential carriers of rabies virus. *Vector Borne Zoonotic Dis*. 2008;8:313–20. <http://dx.doi.org/10.1089/vbz.2007.0209>
 8. Cleaveland S, Appel MGJ, Chalmers WSK, Chillingworth C, Kaare M, Dye C. Serological and demographic evidence for domestic dogs as a source of canine distemper virus infection for Serengeti wildlife. *Vet Microbiol*. 2000;72:217–27. [http://dx.doi.org/10.1016/S0378-1135\(99\)00207-2](http://dx.doi.org/10.1016/S0378-1135(99)00207-2)
 9. Evangelista KV, Coburn J. *Leptospira* as an emerging pathogen, a review of its biology, pathogenesis and host immune responses. *Future Microbiol*. 2010;5:1413–25. <http://dx.doi.org/10.2217/fmb.10.102>
 10. Kolaczinski JH, Reithinger R, Worku DT, Ocheng A, Kasimiro J, Kabatereine N, et al. Risk factors of visceral leishmaniasis in east Africa, a case-control study in Pokot territory of Kenya and Uganda. *Int J Epidemiol*. 2008;37:344–52. <http://dx.doi.org/10.1093/ije/dym275>

Address for correspondence: Javier Millán, Servei d'Ecopatologia de Fauna Salvatge (SEFaS) (Wildlife Diseases Research Group), Departament de Medicina i Cirurgia Animals, Universitat Autònoma de Barcelona, 08193 Bellaterra, Spain; email: syngamu@trachea@hotmail.com

Iatrogenic Creutzfeldt-Jakob Disease from Commercial Cadaveric Human Growth Hormone

To the Editor: Iatrogenic Creutzfeldt-Jakob disease (iCJD) is an acquired form of prion disease that has been declining in incidence since the mid-1990s (1). Worldwide, at least 226 cases of iCJD, including 29 US cases, have been associated with administration of contaminated

human growth hormone (hGH) from cadavers. Reported incubation periods ranged from 5 to 42 years (mean 17 years) (2). Commercially produced cadaveric hGH has been associated with only 1 previously reported case of iCJD: CJD developed in a 39-year-old Austrian man \approx 22 years after he received commercial cadaveric hGH (Crescormon, Kabivitrüm, Stockholm, Sweden) during 1984–1985 (3). We report a second case of probable iCJD acquired through treatment with commercial cadaveric hGH.

The patient was born at 32 weeks' gestation with subsequent developmental delay, agenesis of the corpus callosum, and panhypopituitarism. He demonstrated clinical and laboratory signs of growth hormone deficiency but was denied treatment with hGH through the US government-supported National Hormone and Pituitary Program (NHPP) because he did not meet the height requirement. Treatment with commercial cadaveric hGH began when he was 5.8 years of age and continued for 23 months (1983–1985). He received 1.5 units intramuscularly 3 \times per week and was primarily treated with Asellacrin (Ares-Serono, Geneva, Switzerland). In early 1984, for an unspecified duration, he received Crescormon (Kabivitrüm) because of an Asellacrin shortage. Treatment was halted in 1985 because of iCJD concerns and resumed 2 years later with recombinant hGH.

At age 33, 26.5 years (range 25.5–28 years) after the midpoint of commercial cadaveric hGH treatment, dizziness and gait imbalance developed, causing a fall. The patient's mental status also began declining, and he never returned to his baseline status. Six months after illness onset, he experienced hallucinations, weakness of lower extremities, and limb ataxia. Seven months after the fall, he entered a state of akinetic mutism; he died 9 months after symptom onset. A lumbar puncture,

performed 8 months after illness onset, demonstrated 14-3-3 proteins and an elevated cerebrospinal fluid (CSF) tau level of 14,111 pg/mL (decision point 1,150 pg/mL) (4), although the specimen was contaminated with blood (39,375 erythrocytes/ μ L). Electroencephalogram demonstrated severe diffuse encephalopathy. Two brain magnetic resonance imaging studies performed 8 months after illness onset indicated probable CJD, given lack of prior metabolic and anoxic insults (Figure). The patient was discharged from a referral hospital with this diagnosis; no postmortem analysis was conducted.

On the basis of World Health Organization criteria, we conclude that this patient had probable iCJD as a result of hGH treatment (5). The patient's condition was treated with 2 different formulations of commercial cadaveric hGH, including one of the same brands in the same year as that of the first reported patient with iCJD associated with commercial cadaveric hGH (3). The patient's incubation period (25.5–28 years) is well within expectations (1).

Despite an ongoing active surveillance program that identified \approx 3,500 of \approx 4,500 post-1977 cadaveric hGH recipients in the US NHPP, all 29 CJD infections in NHPP recipients occurred among the estimated \approx 2,700 pre-1977 recipients (1,2). This significant reduction in iCJD was attributed to the 1977 introduction of a highly selective, column chromatography step in the hormone purification protocol that can markedly reduce prion infectivity (1,2). As shown by the many iCJD cases linked to hGH in France, the efficacy of column chromatography purification steps may vary (1). Commercially derived cadaveric hGH was produced in different laboratories from those that produced NHPP-distributed hGH, and sufficient details regarding sourcing and production methods of

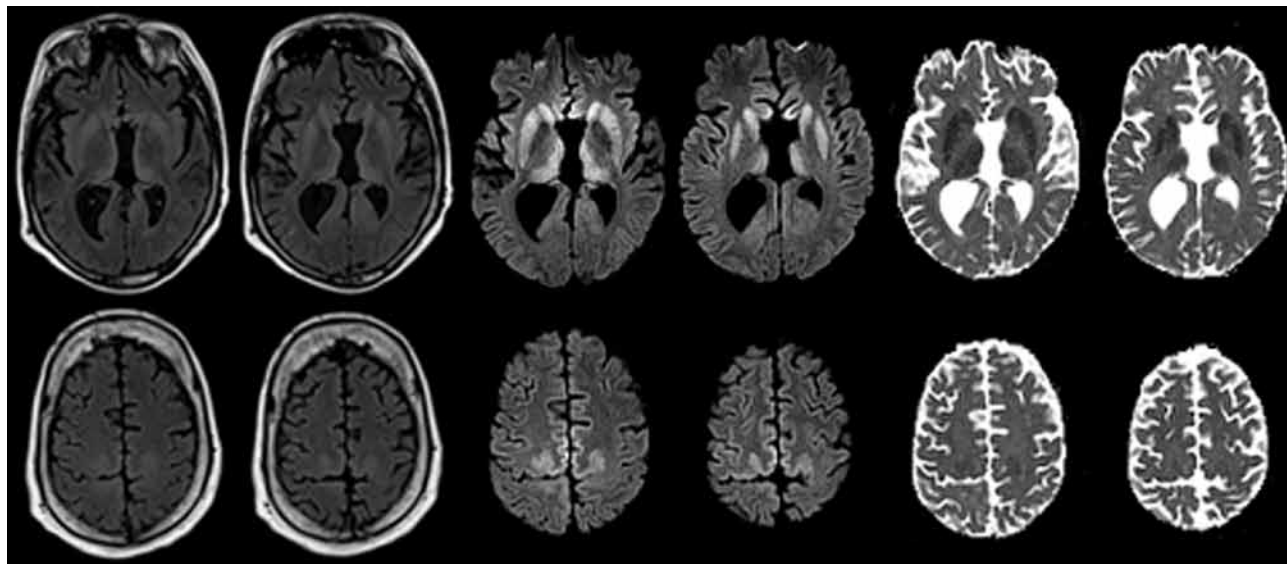


Figure. Maps showing axial fluid attenuated inversion recovery (FLAIR), diffusion-weighted imaging (DWI), and apparent diffusion coefficient (ADC) at the level of the basal nuclei (top row) and dorsal frontoparietal cortex (bottom row) of the brain of a 33.8-year-old man with agenesis of the corpus callosum, schizencephaly, and heterotopia. Note the symmetrical DWI signal hyperintensities in the striatum and dorsomedial part of the thalami. In addition, DWI signal hyperintensities occurred in the cingulate, precuneus and in the dysplastic gray matter along the anterior lips of the schizencephalic clefts at the level of the precentral gyri. The signal abnormalities are associated with decreased diffusivity on ADC maps and are much less prominent on FLAIR images. These findings are highly suggestive of Creutzfeldt-Jakob disease.

the commercial products are lacking. Approximately 10,000 persons, mostly outside the United States, received commercial cadaveric hGH produced by Kabivitrum, and substantially fewer persons received product from Ares-Serono (A.F. Parlow, pers. comm.). Identification through passive surveillance of 2 CJD cases among recipients of such hGH further supports a causal, rather than chance, association between commercial hormone and CJD. It also suggests a difference in iCJD risk between post-1977 NHPP-distributed hGH and commercial cadaveric hGH.

Limitations of this report include the lack of neuropathologic confirmation and insufficient information to strongly implicate a single commercial cadaveric hGH product as infection source. The report of another iCJD case-patient who received Crescormon during the same period provides some evidence that the product was the source of prion contamination. Although the patient may have had sporadic CJD, his young

age at disease onset (33 years) makes this unlikely (6).

This report suggests that a potential risk for iCJD in persons who received commercial cadaveric hGH should be considered. Also, clinicians should not assume that all cadaveric hGH administered after 1977 carries the same risk for infectivity. In addition, when CJD is being considered as a clinical diagnosis, a history of exposure to cadaveric hGH should always be sought, even when patients have normal or tall stature. Finally, we recommend that when a clinical diagnosis of CJD is suspected, but before the patient's death, the local caregivers, with the family, should initiate arrangements for a postmortem examination to confirm diagnosis (e.g., www.cjdsurveillance.com).

Acknowledgments

We thank the National Prion Disease Pathology Surveillance Center for assistance with CSF analyses.

**Brian S. Appleby, Mei Lu,
Alberto Bizzi,
Michael D. Phillips,
Sally M. Berri,
Madeleine D. Harbison, and
Lawrence B. Schonberger**

Author affiliations: Cleveland Clinic Foundation, Cleveland, Ohio, USA (B.S. Appleby, M. Lu, M.D. Phillips); Istituto Clinico Humanitas, Milan, Italy (A. Bizzi); Case Western Reserve University, Cleveland (S.M. Berri); Mount Sinai School of Medicine, New York, New York, USA (M.D. Harbison); and Centers for Disease Control and Prevention, Atlanta, Georgia, USA (L.B. Schonberger)

DOI: <http://dx.doi.org/10.3201/eid1904.121504>

References

1. Brown P, Brandel J-P, Sato T, Nakamura Y, MacKenzie J, Will RG, et al. Iatrogenic Creutzfeldt-Jakob disease, final assessment. *Emerg Infect Dis.* 2012;18:901-7. <http://dx.doi.org/10.3201/eid1806.120116>
2. Abrams JY, Schonberger LB, Belay ED, Maddox RA, Leschek EW, Mills JL, et al. Lower risk of Creutzfeldt-Jakob disease in pituitary grown hormone recipients initiating treatment after 1977. *J Clin Endocrinol Metab.* 2010; 96:e1966-9.

- Furtner M, Gelpi E, Kiechl S, Knoflach M, Zangerl A, Gotwald T, et al. Iatrogenic Creutzfeldt-Jakob disease 22 years after human growth hormone therapy: clinical and radiological features. *J Neurol Neurosurg Psychiatry*. 2008; 79:229–31. <http://dx.doi.org/10.1136/jnnp.2007.122267>
- Hamlin C, Puoti G, Berri S, Sting E, Harris C, Cohen M, et al. A comparison of tau and 14-3-3 protein in the diagnosis of Creutzfeldt-Jakob disease. *Neurology*. 2012;79:547–52. <http://dx.doi.org/10.1212/WNL.0b013e318263565f>
- World Health Organization. Global surveillance, diagnosis and therapy of human transmissible spongiform encephalopathies: report of a WHO consultation. Geneva: The Organization; 1998.
- Appleby BS, Appleby KK, Rabins PV. Does the presentation of Creutzfeldt-Jakob disease vary by age or presumed etiology? A meta-analysis of the past 10 years. *J Neuropsychiatry Clin Neurosci*. 2007;19:428–35. <http://dx.doi.org/10.1176/appi.neuropsych.19.4.428>

Address for correspondence: Brian S. Appleby, Cleveland Clinic Lou Ruvo Center for Brain Health, 9500 Euclid Ave/U10, Cleveland, OH 44195, USA; email: applebb@ccf.org

West Nile Virus Infection in Belgian Traveler Returning from Greece

To the Editor: West Nile virus (WNV) is an arthropod-borne virus that is transmitted to humans by mosquitoes, primarily of the genus *Culex*. Most human infections are asymptomatic. Clinical symptoms occur in ≈20% of case-patients and include

fever, headache, and myalgia; <1% of WNV infections develop into severe neuroinvasive disease (1).

The virus was discovered in 1937 in the West Nile district of Uganda. WNV is endemic to parts of Africa, Europe, Asia, and the Middle East, and since its introduction in New York in 1999, in North America. In Eurasia, human WNV infections were first reported in Israel and France during the 1950s–1960s, and the first major outbreak in Romania occurred in 1996 (1). The disease emerged recently in Greece; a large outbreak in 2010 caused neuroinvasive disease in 197 patients, of whom 33 died (2). Since 2010, occasional and local epidemics have been ongoing in Greece, Italy, Romania, Hungary, Spain, and the Balkans (3,4).

Clinical diagnosis may be difficult because WNV infections resemble other (arbo)viral diseases. Laboratory diagnosis relies primarily on serologic testing. Reverse transcription PCR (RT-PCR) can be used to detect viral RNA during the acute phase of the disease, but its use is hampered by the patient's low-level and transient viremia (1).

We here describe a confirmed case of WNV encephalitis imported by a traveler returning from Greece. A 73-year-old Belgian woman, who had a medical history of lymphoma, traveled to Kavala city (Macedonia, Greece). On August 14, 2012, she sought treatment at the Kavala General Hospital with a 6-day history of fever, headache, malaise, nausea, confusion, decline of consciousness, and neck stiffness. Results of laboratory testing on admission demonstrated an increased leukocyte count (9,670/μL;

80% neutrophils) and lactate dehydrogenase level (522 IU/L), a low C-reactive protein level (0.7 mg/dL), and hyponatremia (131 mEq/L). Cerebrospinal fluid (CSF) testing showed 90 cells/μL (79% lymphocytes) and glucose and protein levels of 72 and 100.9 mg/dL, respectively. Serum obtained on August 15 was sent to the national reference laboratory at Aristotle University (Thessaloniki, Greece), and IgM against WNV was detected by ELISA (WNV IgM Capture DxSelect and IgG DxSelect; Focus Diagnostics, Cypress, CA, USA). IgG was absent. On the second day of hospitalization, the patient exhibited seizures (speech arrest); she was given phenytoin (1/2 amp 3×/day intravenously). On August 18, the patient was transferred to a private hospital. Further treatment included intravenous fluid, antipyretics, antimicrobial drugs, mannitol, and oxygen. On August 30, she was returned by plane to Belgium.

CSF obtained 26 days after symptom onset and serum obtained 29 days after symptom onset were sent to the Institute of Tropical Medicine (Antwerp, Belgium) because of its function as a national reference center for Belgium. IgM and IgG against WNV were detected in both samples by ELISA (Focus Diagnostics) (Table). Immunofluorescence assays on serum revealed IgM against WNV only and IgG against West Nile, dengue, yellow fever, and Japanese encephalitis viruses, with the strongest reaction against WNV (Flavivirus Mosaic 1; Euroimmun, Lübeck, Germany). Real-time RT-PCR (adapted from [5]) on the serum demonstrated a weak positive signal. Repeated RNA extraction and

Table. Laboratory results confirming WNV infection of 73-year-old woman, Greece, 2012*†

Sample	Date	RT-PCR (C _t value)	WNV ELISA IgM (ratio)	WNV ELISA IgG (ratio)	Flavi IFAT IgM	Flavi IFAT IgG
Serum	Aug 15	Positive (45.47)	Positive (25)	Negative	ND	ND
CSF	Sep 3	ND	Positive (5.16)	Positive (2.21)	ND	ND
Serum	Sep 6	Positive (42.87)‡	Positive (4.76)	Positive (2.63)	WNV positive	WNV positive§

*WNV, West Nile virus; RT-PCR, reverse transcription PCR; C_t, cycle threshold; Flavi, flavivirus; IFAT, indirect fluorescent antibody technique; ND, not done; CSF, cerebrospinal fluid.

†The ELISA is positive if ratio >1.1 for IgM and >1.5 for IgG. The cutoff value for IFAT is 1/10 for both IgG and IgM.

‡Sequencing revealed a 116-bp sequence perfectly matched to the WNV amplicon and is highly suggestive for WNV lineage 2 on the basis of the presence of 2 specific nucleotides.

§Strongest signal for WNV, weak signal for other flaviviruses (Japanese encephalitis virus, dengue viruses 1–4, yellow fever virus).