

8. Li TC, Yoshizaki S, Ami Y, Suzaki Y, Yasuda SP, Yoshimatsu K, et al. Susceptibility of laboratory rats against genotypes 1, 3, 4, and rat hepatitis E viruses. *Vet Microbiol.* 2013;163:54–61. <http://dx.doi.org/10.1016/j.vetmic.2012.12.014>
9. Li TC, Suzaki Y, Ami Y, Tsunemitsu H, Miyamura T, Takeda N. Mice are not susceptible to hepatitis E virus infection. *J Vet Med Sci.* 2008;70:1359–62. <http://dx.doi.org/10.1292/jvms.70.1359>
10. John R, Plenge-Bonig A, Hess M, Ulrich RG, Reetz J, Schielke A. Detection of a novel hepatitis E-like virus in faeces of wild rats using a nested broad-spectrum RT-PCR. *J Gen Virol.* 2010;91:750–8. <http://dx.doi.org/10.1099/vir.0.016584-0>

Address for correspondence: Tian-Cheng Li, Department of Virology II, National Institute of Infectious Diseases, 4-7-1 Gakuen, Musashimurayama, Tokyo 208-0011, Japan; email: lite@nih.go.jp

Fatal Case of Enterovirus 71 Infection and Rituximab Therapy, France, 2012

To the Editor: Enterovirus 71 (EV-71) causes primarily asymptomatic or benign infections in children <5 years of age. However, it may cause severe and sometimes fatal neurologic complications, such as brainstem encephalitis and polio-like paralysis (1). Over the last 15 years, large outbreaks of EV-71 infection have been described in the Asia–Pacific region, associated with the regular emergence of new genetic lineages (2). Since the 1978 outbreak in Hungary, rare sporadic cases have been reported in Europe (1). In France, during 2000–2009, a total of 81 hospitalized patients with EV-17 infection were reported by the sentinel surveillance system, including 2 child deaths, 1 due to proven rhombencephalitis (3,4).

We report here a fatal case of EV-71 rhombencephalitis in an immuno-

compromised adult who was receiving rituximab therapy. Rituximab is a chimeric anti-CD20 monoclonal antibody that is widely used for treating B-cell lymphoma and an increasing number of autoimmune diseases. Since rituximab became commercially available, several infectious side-effects for the drug have been reported, including hepatitis B reactivation, progressive multifocal leukoencephalopathy, and enteroviral meningoencephalitis (5). The first 2 cases of rituximab-associated enteroviral meningoencephalitis were reported in 2003 (6), and 5 additional cases have been reported to date (7,8).

In May 2012, a 66-year-old woman was hospitalized in the neurology unit of Bordeaux University Hospital with a 10-day history of fever, asthenia, and psychomotor retardation. She had no history of travel and had not been in close contact with sick persons. She had received a diagnosis of grade I follicular lymphoma 3 years earlier, and it had been treated with 6 cycles of R-CHOP (rituximab, cyclophosphamide, hydroxydaunorubicin, oncovin, prednisolone). Since July 2010, the lymphoma had been in remission, and she had been receiving maintenance therapy with rituximab since that time. The most recent rituximab infusion had been administered in March 2012. Her condition was treated initially with broad-spectrum antibiotics and acyclovir. Still, aphasia, facial paralysis, spastic movements, and consciousness disorders rapidly developed. On day 6, she was transferred to the intensive care unit for ventilatory support.

On patient's admission, blood samples showed lymphopenia (0.64×10^3 cells/mm³) and low immunoglobulin levels, i.e., IgG 4.5 g/L (reference range 6.75–12.8 g/L) and IgM 0.33 g/L (reference range 0.56–1.9 g/L). Three cerebrospinal fluid (CSF) samples were collected on days 1, 4, and 6. CSF leukocyte count rose from 5 to 89 cells/mm³, with lymphocytes from 24% to 95%, and protein levels rose

from 0.68 to 1.03 g/L (reference range 0.15–0.45 g/L). CSF glucose level varied from 3.5 to 4.5 mmol/L (reference range 2.7–3.9 mmol/L). Enterovirus RNA was detected in the patient's first 3 CSF samples and in CSF, stool specimens, and blood until 4 weeks after admission (online Technical Appendix Table 1, wwwnc.cdc.gov/EID/article/19/8/13-0202-Techapp1.pdf). PCR assays of the first 3 CSF samples were negative for JC polyomavirus, herpes simplex virus, varicella-zoster virus, cytomegalovirus, Epstein-Barr virus, human herpesvirus 6, adenovirus, and *Toxoplasma gondii*. Serologic tests for parvovirus B19, mumps virus, and measles virus were IgM negative. Samples were also negative for antibodies against Hu, Ri, Yo, and voltage-gated potassium channel antigens. All bacterial cultures were negative. No evidence for central nervous system infiltration by lymphoma cells was found, on the basis of CSF cytology.

Results of brain magnetic resonance imaging (MRI) scans performed on days 2 and 6 were normal, despite the patient's consciousness disorders (Figure, panel A). However, on day 13, MRI scans showed bilateral and symmetric T2 and FLAIR hypersignals in the medulla, the pons, and the mesencephalon, compatible with rhombencephalitis (Figure, panel B). On day 24, the MRI scan showed a supratentorial extension involving white matter, the insular cortex, and basal ganglia (Figure, panel C). The patient's neurologic condition deteriorated progressively, and she died of enteroviral rhombencephalitis 32 days after admission.

The EV associated with the rhombencephalitis was identified as an EV-71 genogroup C2 isolate by 1D gene complete sequencing and phylogenetic analysis (online Technical Appendix Figure; online Technical Appendix Table 2). The 1D gene sequences determined from cerebrospinal fluid and fecal specimens from the patient showed 95%–97% nucleotide

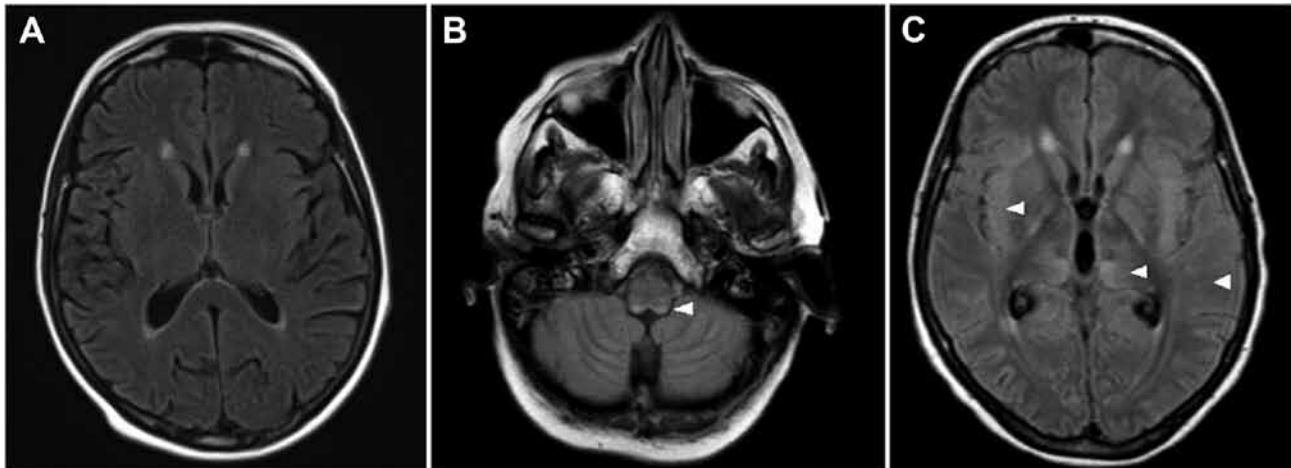


Figure. Magnetic resonance imaging axial flair sequence of brain of 66-year-old woman with fatal encephalitis, Bordeaux, France, 2012. A) No hypersignal at day 6. B) Bilateral posterior hypersignals in the medulla at day 13. C) Bilateral supratentorial hypersignals at day 24 in the cortex, the white matter, and the basal ganglia. Hypersignals are indicated by white arrowheads.

homology and clustered with 1D gene sequences from strains detected during 2006–2012 in France, the Netherlands, Germany, Spain, Canada, United Kingdom, and Singapore.

Only 7 cases of rituximab-associated EV encephalitis have been reported in the literature. Of the case-patients, 3 died from enteroviral meningoencephalitis, 1 showed partial neurologic improvement but died later from another infection (not specified), 2 suffered permanent sequelae, and 1 recovered completely (6–8).

The first case of fatal rituximab-associated EV-71 encephalitis was reported in Australia in 2011 (8). The Australian patient and the French patient reported here were adults, although most EV-71 encephalitis cases have been described in children (1). Neither adult patient exhibited neurogenic pulmonary edema. Both cases were associated with genogroup C2 EV-71 strains that were closely related to those that have been detected in recent years in Europe and worldwide (3).

Because invasive EV infections have been described in adults with hereditary or congenital defects in B-lymphocyte function, humoral immunity is likely to play a key role in EV infection control (9). Passive protection against lethal EV-71 infection

in newborn mice by neutralizing antibodies is another convincing argument that the antibody-mediated response is critical (10). Thus, because rituximab is associated with long-lasting B-cell depletion and, in some patients, a decrease in immunoglobulin, it may lead to an increased risk for EV encephalitis. Although EV encephalitis seems to be rare in patients who receive rituximab treatment, cases may have been underdiagnosed. To detect this condition and prevent possible deaths, physicians should routinely screen for EV RNA in patients receiving anti-CD20 therapy who have neurologic symptoms and should consider the early administration of immunoglobulin.

**Somar Kassab, Tahar Saghi,
Alexandre Boyer,
Marie-Edith Lafon,
Didier Gruson, Bruno Lina,
Hervé Fleury,
and Isabelle Schuffenecker**

Author affiliations: Bordeaux University Hospital and Ségalen Bordeaux University, Bordeaux, France (S. Kassab, T. Saghi, A. Boyer, M.-E. Lafon, D. Gruson, H. Fleury); and French National Reference Center for Enteroviruses—Hospices Civils de Lyon, Bron, France (B. Lina, I. Schuffenecker)

DOI: <http://dx.doi.org/10.3201/eid1907.130202>

References

- Solomon T, Lewthwaite P, Perera D, Cardoso MJ, McMinn P, Ooi MH. Virology, epidemiology, pathogenesis, and control of enterovirus 71. *Lancet Infect Dis*. 2010;10:778–90. [http://dx.doi.org/10.1016/S1473-3099\(10\)70194-8](http://dx.doi.org/10.1016/S1473-3099(10)70194-8)
- McMinn PC. Recent advances in the molecular epidemiology and control of human enterovirus 71 infection. *Curr Opin Virol*. 2012;2:199–205.
- Schuffenecker I, Mirand A, Antona D, Henquell C, Chomel JJ, Archimbaud C, et al. Epidemiology of human enterovirus 71 infections in France, 2000–2009. *J Clin Virol*. 2011;50:50–6. <http://dx.doi.org/10.1016/j.jcv.2010.09.019>
- Vallet S, Legrand Quillien MC, Dailland T, Podeur G, Gouriou S, Schuffenecker I, et al. Fatal case of enterovirus 71 infection, France, 2007. *Emerg Infect Dis*. 2009;15:1837–40. <http://dx.doi.org/10.3201/eid1511.090493>
- Gea-Banacloche JC. Rituximab-associated infections. *Semin Hematol*. 2010;47:187–98. <http://dx.doi.org/10.1053/j.seminhematol.2010.01.002>
- Quartier P, Tourmilhac O, Archimbaud C, Lazaro L, Chaletix C, Millet P, et al. Enteroviral meningoencephalitis after anti-CD20 (rituximab) treatment. *Clin Infect Dis*. 2003;36:e47–9. <http://dx.doi.org/10.1086/345746>
- Servais S, Caers J, Warling O, Frusch N, Baron F, De Prijck B, et al. Enteroviral meningoencephalitis as complication of Rituximab therapy in a patient treated for diffuse large B-cell lymphoma. *Br J Haematol*. 2010;150:379–81. <http://dx.doi.org/10.1111/j.1365-2141.2010.08202.x>
- Ahmed R, Buckland M, Davies L, Halmagyi GM, Rogers SL, Oberste S,

- et al. Enterovirus 71 meningoencephalitis complicating rituximab therapy. *J Neurol Sci.* 2011;305:149–51. <http://dx.doi.org/10.1016/j.jns.2011.03.009>
9. Misbah SA, Spickett PC, Ryba PCJ, Hockaday JM, Kroll JS, Sherwood C, et al. Chronic enteroviral meningoencephalitis in agammaglobulinemia: casereport and literature review. *J Clin Immunol.* 1992;12:266–70. <http://dx.doi.org/10.1007/BF00918150>
 10. Foo DG, Alonso S, Chow VT, Poh CL. Passive protection against lethal enterovirus 71 infection in newborn mice by neutralizing antibodies elicited by a synthetic peptide. *Microbes Infect.* 2007;9:1299–306. <http://dx.doi.org/10.1016/j.micinf.2007.06.002>

Address for correspondence: Isabelle Schuffenecker, Centre National de Référence des Enterovirus, Groupement Hospitalier Est, 59 Bd Pinel, 69677 BRON, France; email: isabelle.schuffenecker@chu-lyon.fr

Norovirus Variant GII.4/Sydney/2012, Bangladesh

To the Editor: Noroviruses (NoVs) are the most common cause of foodborne and waterborne outbreaks of gastroenteritis in persons from all age groups in industrialized and developing countries (1). Although NoV outbreaks occur throughout the year, activity increases in the winter months, especially in the countries with a temperate climate. As expected, during the last few months of 2012, outbreaks of NoV gastroenteritis markedly increased in Europe and the United States (2–4). These increases corresponded with the emergence of a variant of genotype GII.4, Sydney/2012, which was first reported from Australia in March 2012 and, subsequently, in the United States, Belgium, Denmark, Scotland, and Japan (2,5–7).

We identified the NoV GII.4 variant Sydney/2012 through hospital surveillance on diarrhea etiology in

Bangladesh in December 2011 and then throughout 2012. These strains came from 3 hospitals in Dhaka, Matlab, and Mirzapur, where ≈150,000 patients with diarrhea are treated annually. We randomly selected 795 fecal specimens from patients of all ages who sought treatment for diarrhea in these hospitals during 2010–2012 and detected NoV RNA in 90 (33.6%), 72 (27.9%), and 92 (34.2%) samples in 2010, 2011, and 2012, respectively, by performing real-time PCR (8). For characterization, we amplified and sequenced 108 samples on the basis of the capsid genes (9).

Ages of diarrhea patients with NoV infection ranged from 1 month to 91 years (median 15 months; mean 11.9 years). Most (66%) NoV-positive patients were <5 years of age. Infection rates were lowest in patients <3 months (2.1%) and 5–18 years (2.5%) of age. A high number of NoV infections were recorded in adults (28.8% in patients ≥18 years of age). NoVs were detected throughout the year, and no clear seasonal peaks were observed.

Overall, GII was the most predominant genogroup (66.1%), followed by GI (18.1%) and GIV (3.9%). Mixed infections were detected in 11.8% of samples. We observed a high diversity in the GII genogroup and

identified at least 11 different genotypes within the group, in which GII.4 constituted 30.1% of all GII strains. Until December 2011, the GII.4 variant NewOrleans/2009 was the most predominant strain (Figure). However, the new GII.4 variant, Sydney/2012, replaced the old variant and appeared as the dominant strain in 2012. We constructed a phylogenetic tree on the basis of 1,026 bases around the junction region of *pol* and *cap* genes, and it revealed that the newly identified variant has evolved from previous NoV GII.4 variants Apeldoorn/2007 and NewOrleans/2009 (data not shown).

NoVs, old and new, remain a substantial threat to human health, with a new variant emerging every 2–3 years. The Sydney/2012 strain appears to have replaced the previously predominant strain, but its clinical effects and epidemiology are largely unknown and warrant further investigation.

Acknowledgment

We gratefully acknowledge these donors for their support and commitment to the Centre's research efforts.

This work was supported by ICDDR, B (International Centre for Diarrhoeal Disease Research, Bangladesh) and its donors, which provide unrestricted

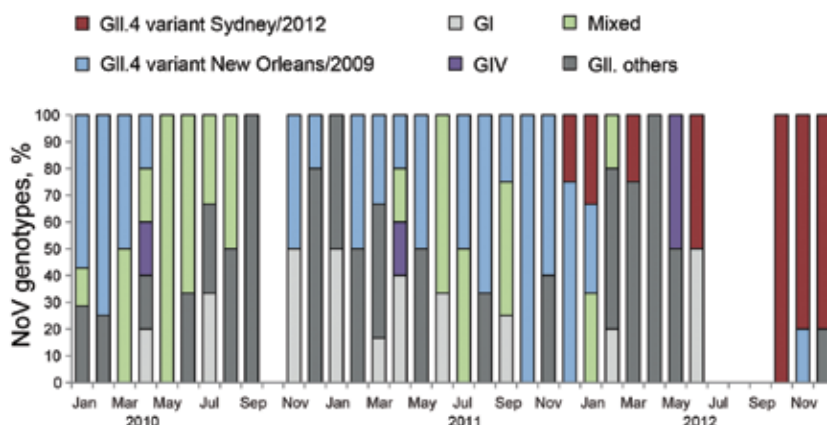


Figure. Distribution of 108 norovirus (NoV) genotypes in Bangladesh, 2010–2012. Bar chart shows the percentage of NoV genotypes. Mixed genotypes comprise NoV GI and GII. GI comprises GI.1, GI.3, GI.4, GI.5, and GI.9. GII.others comprises GII.2, GII.3, GII.4, GII.6, GII.10, GII.13, GII.16, GII.17, and GII.21.

Fatal Case of Enterovirus 71 Infection and Rituximab Therapy, France, 2012

Technical Appendix

Technical Appendix Table 1. PCR results showing enterovirus in CSF, blood, and fecal specimens*

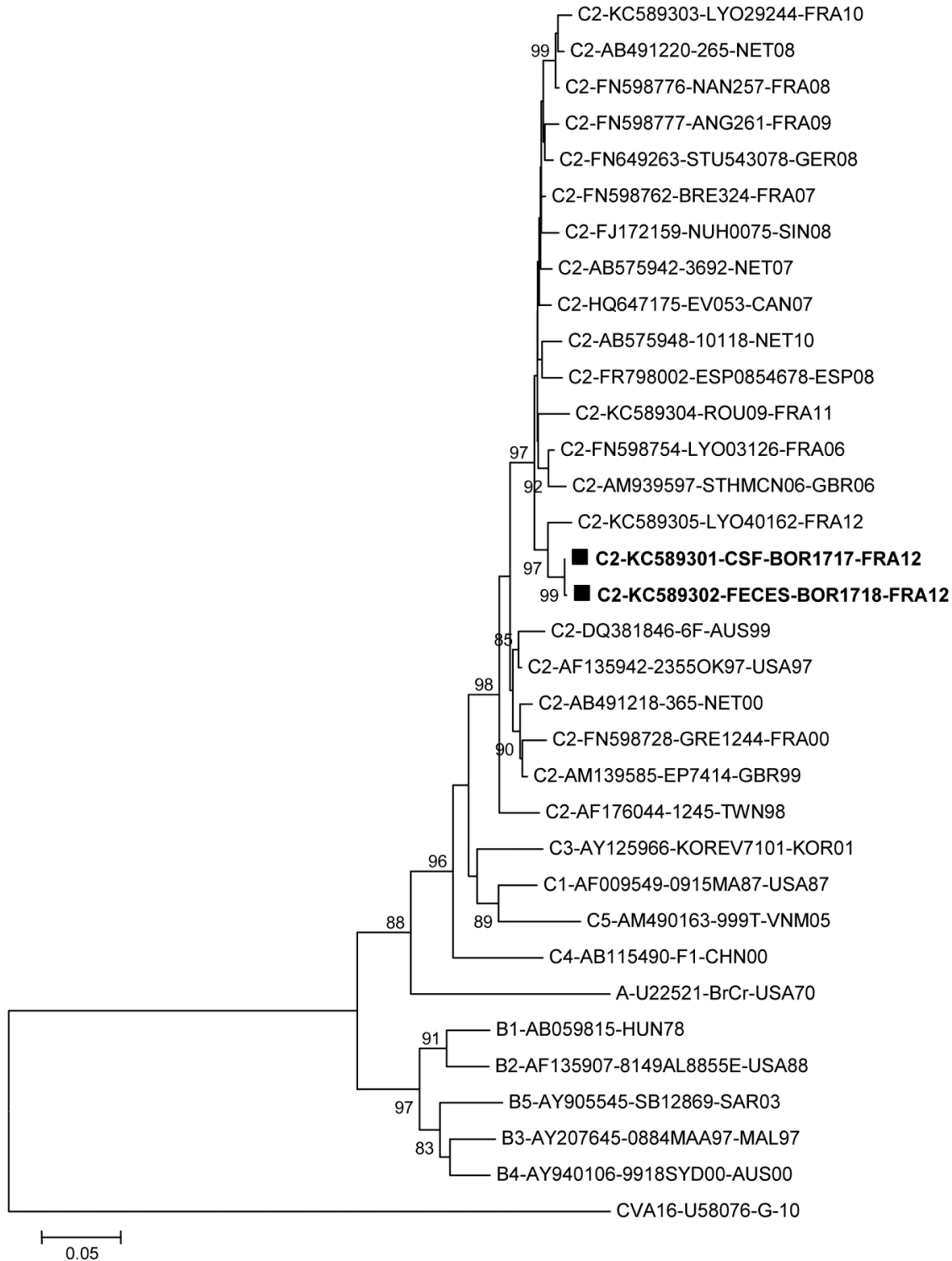
Date specimen obtained, 2012	CSF	Blood	Stool
May 26	+ (35)		
May 29	+ (32)		
May 31	+ (37)	+ (32)	
Jun 4			+ (33)
Jun 6	+ (35)		
Jun 12	+ (24)		+ (29)
Jun 25	+ (28)		

*The cycle threshold is indicated in parentheses. CSF, cerebrospinal fluid.

Technical Appendix Table 2. Enterovirus 71 strains selected for phylogenetic analysis

Genogroup	Origin	Year	Strain	GenBank no.	Diagnosis
A	USA	1970	BrCr	U22521	Meningitis
B1	Hungary	1978	Hungary-78	AB059815	NA
B2	USA	1988	8149-AL-88 55E	AF135907	NA
B3	Malaysia	1997	0884-MAA-97	AY207645	NA
B4	Australia	2000	9918-SYD-00	AY940106	NA
B5	Sarawak	2003	SB12869-SAR-03	AY905545	NA
C1	USA	1987	0915-MA-87	AF009549	NA
C3	Korea	2001	KOR-EV71-01	AY125966	NA
C4	China	2000	F1-CHN-00	AB115490	NA
C5	Vietnam	2005	999T/VNM/05	AM490163	NA
C2	Australia	1999	6F/AUS/6/99	DQ381846	Meningitis
C2	Canada	2007	EV053_07	HQ647175	NA
C2	France	2000	GRE1244_FRA00	FN598728	NA
C2	France	2006	LYO03126_FRA06	FN598754	Meningitis
C2	France	2007	BRE324_FRA07	FN598762	Fatal rhomboencephalitis with neurogenic pulmonary edema
C2	France	2008	NAN257_FRA08	FN598776	NA
C2	France	2009	ANG261_FRA09	FN598777	Myelitis, diarrhea
C2	France	2010	LYO29244_FRA10	This study	Neonatal fever
C2	France	2011	ROU09_FRA11	This study	Neonatal fever, rash
C2	France	2012	LYO40162_FRA12	This study	Acute cerebellar ataxia
C2	France	2012	CSF-BOR1717_FRA12	This study	Fatal rhomboencephalitis
C2	France	2012	FECES-BOR1718_FRA12	This study	Fatal rhomboencephalitis
C2	Great Britain	1999	EP/7414/1999	AM939585	NA
C2	Great Britain	2006	STH/MCN/2006	AM939597	Fatal panencephalitis
C2	Germany	2008	STU543078_GER08	FN649263	NA
C2	Netherlands	2000	365	AB491218	NA
C2	Netherlands	2007	3692	AB575942	NA
C2	Netherlands	2008	265	AB491220	NA
C2	Netherlands	2010	10118	AB575948	NA
C2	Singapore	2008	NUH0075/SIN/08	FJ172159	NA
C2	Spain	2008	ESP08/54678	FR798002	NA
C2	Taiwan	1998	1245a/98/tw	AF176044	HFMD
C2	USA	1997	2355-OK-97	AF135942	NA

*ARDS, acute respiratory distress syndrome; NA, not available; HFMD, hand, foot and mouth disease.



Technical Appendix Figure. Phylogenetic analysis of complete viral protein 1 coding sequences of enterovirus (EV) 71 strains. The analysis included the sequences determined from the cerebrospinal and stool specimens collected from the patient with fatal rhombencephalitis (shown by a square), 8 selected genogroup C2 sequences from French strains (detected between 2000 and 2012), and 23 Gen-Bank-

selected worldwide strains. The prototype coxsackievirus A16 strain was used as an outgroup virus. Genetic distances were calculated with the Maximum Composite Likelihood model of evolution. The tree was constructed by the neighbor-joining method, using MEGA5, and validated using 1,000 bootstrap pseudo-replicates. Designation of strains was as follows: subgenogroup of the strain/GenBank accession number/lab number of the isolate/3-letter country code/ year of detection.