

# Severe Murine Typhus with Pulmonary System Involvement

Thomas W. van der Vaart, Pieter P.A.M. van Thiel,  
Nicole P. Juffermans, Michèle van Vugt,  
Suzanne E. Geerlings, Martin P. Grobusch,  
and Abraham Goorhuis

We encountered a case of severe murine typhus complicated by acute respiratory distress syndrome. To determine worldwide prevalence of such cases, we reviewed the literature and found that respiratory symptoms occur in ≈30% of murine typhus patients. In disease-endemic areas, murine typhus should be considered for patients with respiratory symptoms and fever.

Murine typhus (endemic typhus) is a febrile illness caused by fleaborne *Rickettsia typhi*; it occurs mainly in environments where rats and humans live in close proximity. Murine typhus is found worldwide, but most reported cases originate from Southeast Asia, the Mediterranean region, and the United States. Among travelers, murine typhus is most frequently associated with travel to Southeast Asia (1). Recently, 2 cases of severe murine typhus with pulmonary manifestations have been reported (2,3). Near the same time, the Academic Medical Center (Amsterdam, the Netherlands) admitted a patient with severe murine typhus and respiratory failure. On the basis of these 3 cases, we hypothesized that pulmonary system involvement of murine typhus might be more common than previously assumed. We conducted this study because data on prevalence of pulmonary involvement in murine typhus are rarely reported. We therefore describe a clinical case and summarize the published literature on the pulmonary aspects of murine typhus.

## The Study

In February 2012, a previously healthy 40-year-old man visited the Academic Medical Center outpatient department, reporting fever, headache, sweating, and nausea. The signs and symptoms had started 1 day earlier, on the day of his return from a 1-month holiday in Borneo. He reported frequent insect bites and exposure to fresh water. He had taken malaria chemoprophylaxis as recommended, and

his vaccinations were up to date. Physical examination indicated that he was afebrile, was hemodynamically stable, and had a discrete macular rash on the trunk but no eschar. Laboratory results showed a hemoglobin concentration (16.8 g/dL) within reference range, a leukocyte count of 4,700 cells/mm<sup>3</sup> with lymphopenia (1,090 cells/mm<sup>3</sup>), and thrombocytopenia (116,000 cells/mm<sup>3</sup>). C-reactive protein (42 mg/L) and serum creatinine (1.32 mg/dL) concentrations were moderately elevated. A thick smear showed no plasmodia, and a dengue antigen test result was negative. By the next day, the patient's condition had deteriorated; he was experiencing chills, his temperature was 39°C, and the rash had become more pronounced. He was admitted to the hospital and given doxycycline (200 mg twice a day) for suspected rickettsiosis or leptospirosis. After admission, his condition deteriorated further; increasing dyspnea progressed to respiratory failure, necessitating intubation and admission to the intensive care unit on the second day after admission.

Chest radiographs revealed bilateral interstitial abnormalities (Figure). His condition fit a diagnosis of acute respiratory distress syndrome (ARDS). Empirical treatment was expanded to include broad-spectrum antimicrobial drugs and oseltamivir.

On the fourth day of intubation, the patient's condition improved; he was extubated 1 day later. Cultured blood, urine, and bronchial fluid remained sterile, and test results for *Leptospira*, *Legionella*, influenza virus, and HIV were negative. All antimicrobial drugs except doxycycline were discontinued; doxycycline was continued for a total of 14 days.

Serum collected 1 day after admission showed weakly positive IgG against *R. typhi*; after 7 days, the immunofluorescent antibody titer had increased 4-fold (from 1:64 to >1:256). The patient recovered completely and was doing well at his last follow-up visit.

To determine prevalence of such cases, we conducted a search of published studies mentioning pulmonary manifestations of murine typhus (details in the online Technical Appendix, <http://wwwnc.cdc.gov/EID/article/20/8/13-1421-Techapp1.pdf>). From 779 records, we selected 22 cohort studies and 18 case studies that, according to title and abstract, were relevant to our research question. We differentiated between studies with individual patient data (case reports and case series) and studies without individual patient data (cohort studies). For each study, we recorded year of publication, study design, and country of infection. We also recorded the presence of pulmonary involvement, defined as cough and any mention of an abnormal finding on chest radiograph, without further distinction.

An overview of study characteristics detailing prevalence of cough and chest radiograph abnormalities is provided in the online Technical Appendix Table 1. Two

Author affiliation: Academic Medical Center, Amsterdam, the Netherlands

DOI: <http://dx.doi.org/10.3201/eid2008.131421>

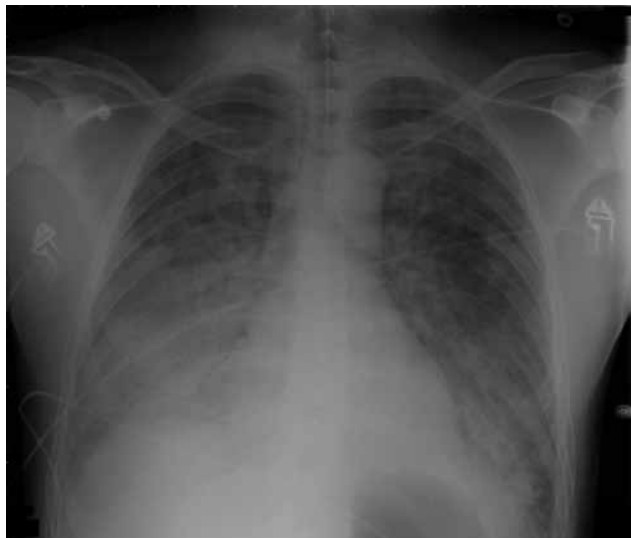

Figure. Chest radiograph of 40-year-old man with acute respiratory distress syndrome as a complication of murine typhus.

studies were prospective population-based studies of the causative agent of fever of unknown origin. The remaining 20 studies were all *Rickettsia* spp. specific; in 17 of these studies, patients had been recruited retrospectively from hospital databases or chart reviews.

The 22 study reports that contained data on the presence or absence of cough together accounted for 1,060 patients with murine typhus. The prevalence of cough among these patients ranged from 0 to 66%. Mean prevalence (all patients from all studies combined) of cough was 30.1% (95% CI 23.3–36.9).

Data on presence or absence of radiographic abnormalities were mentioned in 9 study reports (4–12). Taken together, these studies evaluated 621 patients and 104 chest radiographs showing abnormalities, leading to a prevalence rate of chest radiograph abnormalities of 16.7% (95% CI 8.21–25.5). The cohort studies reported 2 cases of ARDS, 1

with a fatal outcome. The Table shows the full-text descriptions of chest radiograph abnormalities.

Pulmonary manifestations were also documented by the case studies. Among these studies, 2 patients had ARDS, 7 had bilateral pulmonary infiltrates, 5 had unilateral pulmonary infiltrates, 1 had pulmonary embolism, and 1 had respiratory failure (no chest radiograph was reported) (online Technical Appendix Table 2). We also found that cough occurred more commonly among patients in studies conducted in Asia (99 [38.2%] of 259 patients) than among those in studies conducted in the Mediterranean region (118 [25.8%] of 457) and North America (56 [23.3%] of 240).

In the literature, we found 7 reported cases of respiratory distress associated with murine typhus (including the case reported here), 2 of which described respiratory distress not classified as ARDS (2,13). Of these 7 case-patients with ARDS/respiratory distress, 5 (71%) patients were from Asia (2,3,11,13), 1 was from the Mediterranean region (4), and 1 was from the United States (14).

## Conclusions

Cough and chest radiograph abnormalities were frequent manifestations of murine typhus. For cough associated with murine typhus, we found a prevalence rate of ≈30%. The prevalence of chest radiograph abnormalities was more difficult to ascertain because this result was less often reported and more influenced by bias. The pulmonary aspects of *R. typhi* infection are probably the result of damaged pulmonary microcirculation, leading to pulmonary edema.

Severe pulmonary manifestations of murine typhus are thought to be rare. The case reported here is unusual in that the symptoms progressed rapidly and the response to doxycycline was relatively slow. It is worth noting that we found no more than 2 reported cases of fatal murine typhus associated with pulmonary system disease; both were the result of severe disease complicated by ARDS.

Table. Pulmonary manifestations of murine typhus reported from cohort studies\*

Reference	Year	Region	No. cases	No. chest radiographs	No. chest radiographs showing abnormalities	Details
(5)	2001	USA	97	81	10	Radiographic evidence of pneumonitis in 10/81 cases
(6)	2004	Mediterranean	87	NM	6	4 cases of pulmonary infiltrates, 2 cases of pleural effusion
(7)	2008	Asia	50	16	6	6 cases of pulmonary infiltrates
(8)	2009	Mediterranean	41	NM	22	Abnormal chest radiographs for 22 patients
(9)	2009	Asia	28	15	9	9 bilateral reticulonodular infiltrates
(10)	2012	Mediterranean	90	NM	15	13 cases of interstitial pneumonia, 2 cases of pleural effusion
(11)	2012	Asia	81	49	16	15 cases of pulmonary infiltrates, 1 case of ARDS
(12)	2013	Mediterranean	43	39	12	2 cases of alveolar infiltrates, 10 cases of interstitial infiltrates

\*NM, not mentioned; ARDS, acute respiratory distress syndrome.

In addition, we noted possible geographic variation in pulmonary manifestations. Most cases of severe murine typhus with pulmonary manifestations originated in Asia, and cough was more frequently a symptom among patients in Asia.

The primary strength of our study is the extensive literature search, which covered studies from different parts of the world and included cohort studies and case series. The main limitation of this study is the retrospective nature of the data collection for most studies, which is prone to bias and renders meaningful statistical analysis of results impossible. Therefore, prospective studies evaluating pulmonary manifestations of murine typhus and possible geographic variation are needed.

Although murine typhus usually follows a benign course, severe disease with pulmonary manifestations, including ARDS, can occur, as described for the patient reported here. We suggest that murine typhus should be included in the differential diagnosis for any patient who has a fever and respiratory signs and who has been in a typhus-endemic area within the incubation period.

Mr van der Vaart is a sixth-year medical student at the Academic Medical Center of the University of Amsterdam and is currently enrolled in his clinical rotations. His main research focus is infectious diseases.

## References

- Jensenius M, Han PV, Schlegelhauf P, Schwartz E, Parola P, Castelli F, et al. Acute and potentially life-threatening tropical diseases in western travelers—a GeoSentinel multicenter study, 1996–2011. *Am J Trop Med Hyg.* 2013;88:397–404. <http://dx.doi.org/10.4269/ajtmh.12-0551>
- Stockdale AJ, Weekes MP, Kiely B, Lever AM. Case report: severe typhus group rickettsiosis complicated by pulmonary edema in a returning traveler from Indonesia. *Am J Trop Med Hyg.* 2011;85:1121–3. <http://dx.doi.org/10.4269/ajtmh.2011.11-0340>
- Sakamoto N, Nakamura-Uchiyama F, Kobayashi K, Takasaki T, Ogasawara Y, Ando S, et al. Severe murine typhus with shock and acute respiratory failure in a Japanese traveler after returning from Thailand. *J Travel Med.* 2013;20:50–3. <http://dx.doi.org/10.1111/j.1708-8305.2012.00678.x>
- Bernabeu-Wittel M, Pachon J, Alarcon A, Lopez-Cortes LF, Viciano P, Jimenez-Mejias ME, et al. Murine typhus as a common cause of fever of intermediate duration: a 17-year study in the south of Spain. *Arch Intern Med.* 1999;159:872–6. <http://dx.doi.org/10.1001/archinte.159.8.872>
- Whiteford SF, Taylor JP, Dumler JS. Clinical, laboratory, and epidemiologic features of murine typhus in 97 Texas children. *Arch Pediatr Adolesc Med.* 2001;155:396–400. <http://dx.doi.org/10.1001/archpedi.155.3.396>
- Gikas A, Doukakis S, Padiaditis J, Kastanakis S, Manios A, Tselentis Y. Comparison of the effectiveness of five different antibiotic regimens on infection with *Rickettsia typhi*: therapeutic data from 87 cases. *Am J Trop Med Hyg.* 2004;70:576–9.
- Zimmerman MD, Murdoch DR, Rozmajzl PJ, Basnyat B, Woods CW, Richards AL, et al. Murine typhus and febrile illness, Nepal. *Emerg Infect Dis.* 2008;14:1656–9. <http://dx.doi.org/10.3201/eid1410.080236>
- Gikas A, Kokkini S, Tsioutis C, Athenessopoulos D, Balomenaki E, Blasak S, et al. Murine typhus in children: clinical and laboratory features from 41 cases in Crete, Greece. *Clin Microbiol Infect.* 2009;15(Suppl 2):211–2. doi: 10.1111/j.1469-0691.2008.02133.x
- Suputtamongkol Y, Suttinont C, Niwatayakul K, Hoontrakul S, Limpaboon R, Chierakul W, et al. Epidemiology and clinical aspects of rickettsioses in Thailand. *Ann N Y Acad Sci.* 2009;1166:172–9. <http://dx.doi.org/10.1111/j.1749-6632.2009.04514.x>
- Chalioitis G, Kritsotakis EI, Psaroulaki A, Tselentis Y, Gikas A. Murine typhus in central Greece: epidemiological, clinical, laboratory, and therapeutic-response features of 90 cases. *Int J Infect Dis.* 2012;16:e591-6. doi: 10.1016/j.ijid.2012.03.010
- Chang K, Chen YH, Lee NY, Lee HC, Lin CY, Tsai JJ, et al. Murine typhus in southern Taiwan during 1992–2009. *Am J Trop Med Hyg.* 2012;87:141–7. <http://dx.doi.org/10.4269/ajtmh.2012.11-0465>
- Znazen A, Hammami B, Mustapha AB, Chaari S, Lahiani D, Maaloul I, et al. Murine typhus in Tunisia: a neglected cause of fever as a single symptom. *Med Mal Infect.* 2013;43:226–9. <http://dx.doi.org/10.1016/j.medmal.2013.02.007>
- Tan L, Beersma TM, van Beek Y, van Genderen PJ. Two travellers suffering from typhus [in Dutch]. *Ned Tijdschr Geneeskd.* 2011;155:A3845.
- Walker DH, Parks FM, Betz TG, Taylor JP, Muehlberger JW. Histopathology and immunohistologic demonstration of the distribution of *Rickettsia typhi* in fatal murine typhus. *Am J Clin Pathol.* 1989;91:720–4.

Address for correspondence: Abraham Goorhuis, Center for Tropical and Travel Medicine, Division of Infectious Diseases, Department of Internal Medicine, Academic Medical Center, University of Amsterdam, Meibergdreef 9, Room F4-217, 1105 AZ Amsterdam, the Netherlands; email: a.goorhuis@amc.uva.nl

**Medscape**  
**CME**

Sign up to receive email announcements when  
a new article is available.

Get an online subscription at [wwwnc.cdc.gov/eid/subscribe.htm](http://wwwnc.cdc.gov/eid/subscribe.htm)

# Severe Murine Typhus with Pulmonary System Involvement

## Technical Appendix

### Search Strategy

We searched MEDLINE with the search terms “Rickettsia typhi”[Mesh] OR (rickettsi\*[tiab] AND typhi[tiab]) OR “Typhus, Endemic Flea-Borne”[Mesh] OR (murine[tiab] AND typhus[tiab]) OR (flea-borne[tiab] AND typhus[tiab]) OR endemic typhus[tiab] for articles published from 1 January 1975 to 1 January 2014. Only articles published in English or in Dutch were included. Articles were first selected on the basis of title and abstract, and subsequently on the possibility of containing data on pulmonary symptoms of murine typhus. Full texts of selected articles were read to identify studies containing patient data. Technical Appendix Figure 1 details the selection process.

Technical Appendix Table 1. Overview of cohort studies of murine typhus

Reference	Year	Country	Patient sample	No. cases	Prevalence of cough, %	Prevalence of chest radiograph abnormalities, %
(1)	1982	Kuwait	Retrospective cohort	104	44	
(2)	1991	USA	Retrospective cohort	80	35	
(3)	1991	Thailand	Retrospective cohort	10	40	
(4)	1992	Greece	Retrospective cohort	49	37	
(5)	1999	Spain	Retrospective cohort	104	25	7
(6)	2000	USA	Retrospective cohort	30	40	
(7)	2001	Singapore	Retrospective cohort	21	43	
(8)	2001	USA	Retrospective cohort	97	10	10
(9)	2003	Sri Lanka	Prospective cohort	2	0	
(10)	2003	Thailand	Prospective cohort	4	25	
(11)	2004	Greece	Retrospective cohort	87	30	7
(12)	2004	Greece	Retrospective cohort	22	27	
(13)	2006	Laos	Prospective cohort	41	34	
(14)	2007	Greece	Retrospective cohort	21	19	
(15)	2008	Nepal	Retrospective cohort	50	66	12
(16)	2009	Greece	Retrospective cohort	41	10	54
(17)	2009	Thailand	Retrospective cohort	28	32	32
(18)	2010	USA	Retrospective	33	18	

Reference	Year	Country	Patient sample cohort	No. cases	Prevalence of cough, %	Prevalence of chest radiograph abnormalities, %
(19)	2012	Greece	Prospective cohort	90	32	14
(20)	2012	Taiwan	Retrospective cohort	81	26	19
(21)	2012	Nepal	Prospective cohort	22	36	
(22)	2013	Tunisia	Retrospective cohort	43	12	28

Technical Appendix Table 2. Overview of case studies detailing chest radiograph abnormalities\*

Reference	Year	Region	No. patients	Details as provided in full text
(23)	1986	Mediterranean	1	Pulmonary embolism
(24)	1989	USA	1	ARDS
(25)	1997	Asia	1	Unilateral pulmonary infiltrates
(26)	2003	USA	1	Bilateral pulmonary edema and pleural effusion
(27)	2005	Mediterranean	4	3 cases of interstitial pneumonia, 1 case of alveolar infiltrates
(28)	2010	Asia	1	Unilateral pulmonary infiltrates
(29)	2010	USA	1	Unilateral pulmonary infiltrates
(30)	2011	Asia	1	Bilateral pulmonary infiltrates
(31)	2011	Asia	1	Bilateral pulmonary infiltrates
(32)	2011	Asia	1	Respiratory failure without a reported chest radiograph
(33)	2012	Mediterranean	2	unilateral pulmonary infiltrates
(34)	2013	Asia	1	ARDS

\*Six more articles only mention cough as a symptom and are not included in this table. References are available on request. ARDS, acute respiratory distress syndrome.

## References

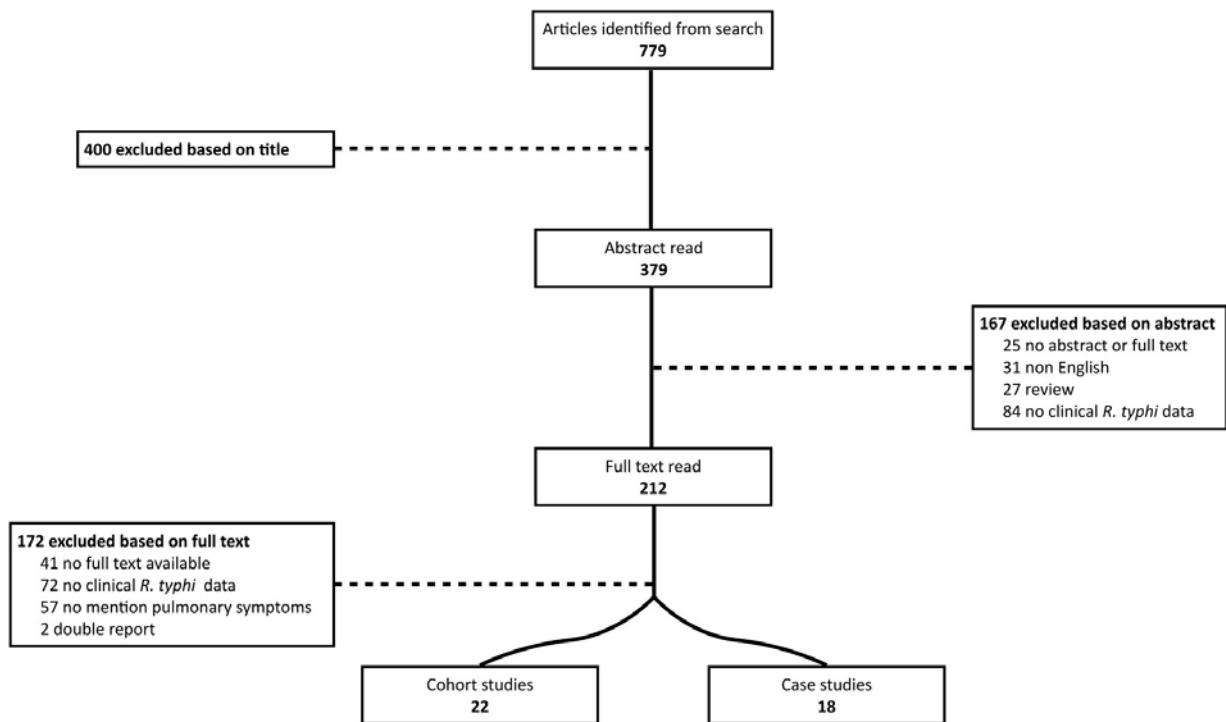
1. Al-Awadi AR, Al-Kazemi N, Ezzat G, Saah AJ, Shepard C, Zaghoul T, et al. Murine typhus in Kuwait in 1978. *Bull World Health Organ.* 1982;60:283–9. [PubMed](#)
2. Dumler JS, Taylor JP, Walker DH. Clinical and laboratory features of murine typhus in south Texas, 1980 through 1987. *JAMA.* 1991;266:1365–70. [PubMed](#)  
<http://dx.doi.org/10.1001/jama.1991.03470100057033>
3. Silpapojakul K, Chupuppakarn S, Yuthasompob S, Varachit B, Chaipak D, Borkerd T. Scrub and murine typhus in children with obscure fever in the tropics. *Pediatr Infect Dis J.* 1991;10:200–3. [PubMed](#) <http://dx.doi.org/10.1097/00006454-199103000-00006>
4. Tselentis Y, Babalis TL, Chrysanthis D, Gikas A, Chaliotis G, Raoult D. Clinicoepidemiological study of murine typhus on the Greek island of Evia. *Eur J Epidemiol.* 1992;8:268–72. [PubMed](#)  
<http://dx.doi.org/10.1007/BF00144812>
5. Bernabeu-Wittel M, Pachon J, Alarcon A, Lopez-Cortes LF, Viciano P, Jimenez-Mejias ME, et al. Murine typhus as a common cause of fever of intermediate duration: a 17-year study in the south of Spain. *Arch Intern Med.* 1999;159:872–6. [PubMed](#)  
<http://dx.doi.org/10.1001/archinte.159.8.872>
6. Fergie JE, Purcell K, Wanat D. Murine typhus in South Texas children. *Pediatr Infect Dis J.* 2000;19:535–8. [PubMed](#) <http://dx.doi.org/10.1097/00006454-200006000-00009>

7. Ong AK, Tambyah PA, Ooi S, Kumarasinghe G, Chow C. Endemic typhus in Singapore—a re-emerging infectious disease? *Singapore Med J*. 2001;42:549–52. [PubMed](#)
8. Whiteford SF, Taylor JP, Dumler JS. Clinical, laboratory, and epidemiologic features of murine typhus in 97 Texas children. *Arch Pediatr Adolesc Med*. 2001;155:396–400. [PubMed](#)  
<http://dx.doi.org/10.1001/archpedi.155.3.396>
9. Kularatne SA, Edirisingha JS, Gawarammana IB, Urakami H, Chenchittikul M, Kaiho I. Emerging rickettsial infections in Sri Lanka: the pattern in the hilly Central Province. *Trop Med Int Health*. 2003;8:803–11. [PubMed](#) <http://dx.doi.org/10.1046/j.1365-3156.2003.01108.x>
10. Parola P, Miller RS, McDaniel P, Telford SR III, Rolain JM, Wongsrichanalai C, et al. Emerging rickettsioses of the Thai-Myanmar border. *Emerg Infect Dis*. 2003;9:592–5. [PubMed](#)  
<http://dx.doi.org/10.3201/eid0905.020511>
11. Gikas A, Doukakis S, Padiaditis J, Kastanakis S, Manios A, Tselentis Y. Comparison of the effectiveness of five different antibiotic regimens on infection with *Rickettsia typhi*: therapeutic data from 87 cases. *Am J Trop Med Hyg*. 2004;70:576–9. [PubMed](#)
12. Hernández-Cabrera M, Angel-Moreno A, Santana E, Bolanos M, Frances A, Martin-Sanchez MS, et al. Murine typhus with renal involvement in Canary Islands, Spain. *Emerg Infect Dis*. 2004;10:740–3. [PubMed](#) <http://dx.doi.org/10.3201/eid1004.030532>
13. Phongmany S, Rolain JM, Phetsouvanh R, Blacksell SD, Soukhaseum V, Rasachack B, et al. Rickettsial infections and fever, Vientiane, Laos. *Emerg Infect Dis*. 2006;12:256–62. [PubMed](#)  
<http://dx.doi.org/10.3201/eid1202.050900>
14. Koliou M, Psaroulaki A, Georgiou C, Ioannou I, Tselentis Y, Gikas A. Murine typhus in Cyprus: 21 paediatric cases. *Eur J Clin Microbiol Infect Dis*. 2007; ;26:491–3. PMID: 17554571
15. Zimmerman MD, Murdoch DR, Rozmajzl PJ, Basnyat B, Woods CW, Richards AL, et al. Murine typhus and febrile illness, Nepal. *Emerg Infect Dis*. 2008;14:1656–9. [PubMed](#)  
<http://dx.doi.org/10.3201/eid1410.080236>
16. Gikas A, Kokkini S, Tsioutis C, Athenessopoulos D, Balomenaki E, Blasak S, et al. Murine typhus in children: clinical and laboratory features from 41 cases in Crete, Greece. *Clin Microbiol Infect*. 2009;15 (Suppl 2):211–2. PMID19374652
17. Suputtamongkol Y, Suttinont C, Niwatayakul K, Hoontrakul S, Limpiboon R, Chierakul W, et al. Epidemiology and clinical aspects of rickettsioses in Thailand. *Ann N Y Acad Sci*. 2009;1166:172–9. [PubMed](#) <http://dx.doi.org/10.1111/j.1749-6632.2009.04514.x>

18. Adjemian J, Parks S, McElroy K, Campbell J, Eremeeva ME, Nicholson WL, et al. Murine typhus in Austin, Texas, USA, 2008. *Emerg Infect Dis.* 2010;16:412–7. [PubMed](#)  
<http://dx.doi.org/10.3201/eid1603.091028>
19. Chaliotis G, Kritsotakis EI, Psaroulaki A, Tselentis Y, Gikas A. Murine typhus in central Greece: epidemiological, clinical, laboratory, and therapeutic-response features of 90 cases. *Int J Infect Dis.* 2012;16:e591–6. **PMID: 22658872** **doi: 10.1016/j.ijid.2012.03.010.**
20. Chang K, Chen YH, Lee NY, Lee HC, Lin CY, Tsai JJ, et al. Murine typhus in southern Taiwan during 1992–2009. *Am J Trop Med Hyg.* 2012;87:141–7. [PubMed](#)  
<http://dx.doi.org/10.4269/ajtmh.2012.11-0465>
21. Pradhan R, Shrestha U, Gautam SC, Thorson S, Shrestha K, Yadav BK, et al. Bloodstream infection among children presenting to a general hospital outpatient clinic in urban Nepal. *PLoS ONE.* 2012;7:e47531. [PubMed](#) <http://dx.doi.org/10.1371/journal.pone.0047531>
22. Znazen A, Hammami B, Mustapha AB, Chaari S, Lahiani D, Maaloul I, et al. Murine typhus in Tunisia: a neglected cause of fever as a single symptom. *Med Mal Infect.* 2013;43:226–9. [PubMed](#) <http://dx.doi.org/10.1016/j.medmal.2013.02.007>
23. Potasman I, Bassan HM. Pulmonary embolism complicating murine typhus. *J R Soc Med.* 1986;79:367–8. [PubMed](#)
24. Walker DH, Parks FM, Betz TG, Taylor JP, Muehlberger JW. Histopathology and immunohistologic demonstration of the distribution of *Rickettsia typhi* in fatal murine typhus. *Am J Clin Pathol.* 1989;91:720–4. [PubMed](#)
25. Lu TM, Kuo BI, Chung YM, Liu CY. Murine typhus presenting with multiple white dots in the retina. *Scand J Infect Dis.* 1997;29:632–3. [PubMed](#)  
<http://dx.doi.org/10.3109/00365549709035910>
26. Centers for Disease Control and Prevention. Murine typhus—Hawaii, 2002. *MMWR Morb Mortal Wkly Rep.* 2003;52:1224–6. [PubMed](#)
27. Letaief AO, Kaabia N, Chakroun M, Khalifa M, Bouzouaia N, Jemni L. Clinical and laboratory features of murine typhus in central Tunisia: a report of seven cases. *Int J Infect Dis.* 2005;9:331–4. **PMID: 16054415**
28. Lin SY, Wang YL, Lin HF, Chen TC, Chen YH, Lu PL. Reversible hearing impairment: delayed complication of murine typhus or adverse reaction to azithromycin? *J Med Microbiol.* 2010;59:602–6. [PubMed](#) <http://dx.doi.org/10.1099/jmm.0.013813-0>

29. Restrepo MI, Vasquez EM, Echeverri C, Fiebelkorn KR, Anstead GM. Fibrin ring granulomas in *Rickettsia typhi* infection. *Diagn Microbiol Infect Dis*. 2010;66:322–5. [PubMed](#)  
<http://dx.doi.org/10.1016/j.diagmicrobio.2009.10.019>
30. Schulze MH, Keller C, Muller A, Ziegler U, Langen HJ, Hegasy G, et al. *Rickettsia typhi* infection with interstitial pneumonia in a traveler treated with moxifloxacin. *J Clin Microbiol*. 2011;49:741–3. [PubMed](#) <http://dx.doi.org/10.1128/JCM.01201-10>
31. Stockdale AJ, Weekes MP, Kiely B, Lever AM. Case report: Severe typhus group rickettsiosis complicated by pulmonary edema in a returning traveler from Indonesia. *Am J Trop Med Hyg*. 2011;85:1121–3. [PubMed](#) <http://dx.doi.org/10.4269/ajtmh.2011.11-0340>
32. Tan L, Beersma TM, van Beek Y, van Genderen PJ. [Two travellers suffering from typhus]. *Ned Tijdschr Geneeskd*. 2011;155:A3845. [PubMed](#)
33. Velasco-Tirado V, Hernandez-Cabrera M, Pisos-Alamo E, Perez-Arellano JL. *Rickettsia typhi*. A new causative agent of round pneumonia in adults. *Enferm Infecc Microbiol Clin*. 2012;30:427–8. [PubMed](#) <http://dx.doi.org/10.1016/j.eimc.2012.02.008>
34. Sakamoto N, Nakamura-Uchiyama F, Kobayashi K, Takasaki T, Ogasawara Y, Ando S, et al. Severe murine typhus with shock and acute respiratory failure in a Japanese traveler after returning from Thailand. *J Travel Med*. 2013;20:50–3. [PubMed](#)  
<http://dx.doi.org/10.1111/j.1708-8305.2012.00678.x>





Technical Appendix Figure. Flowchart of study selection process.