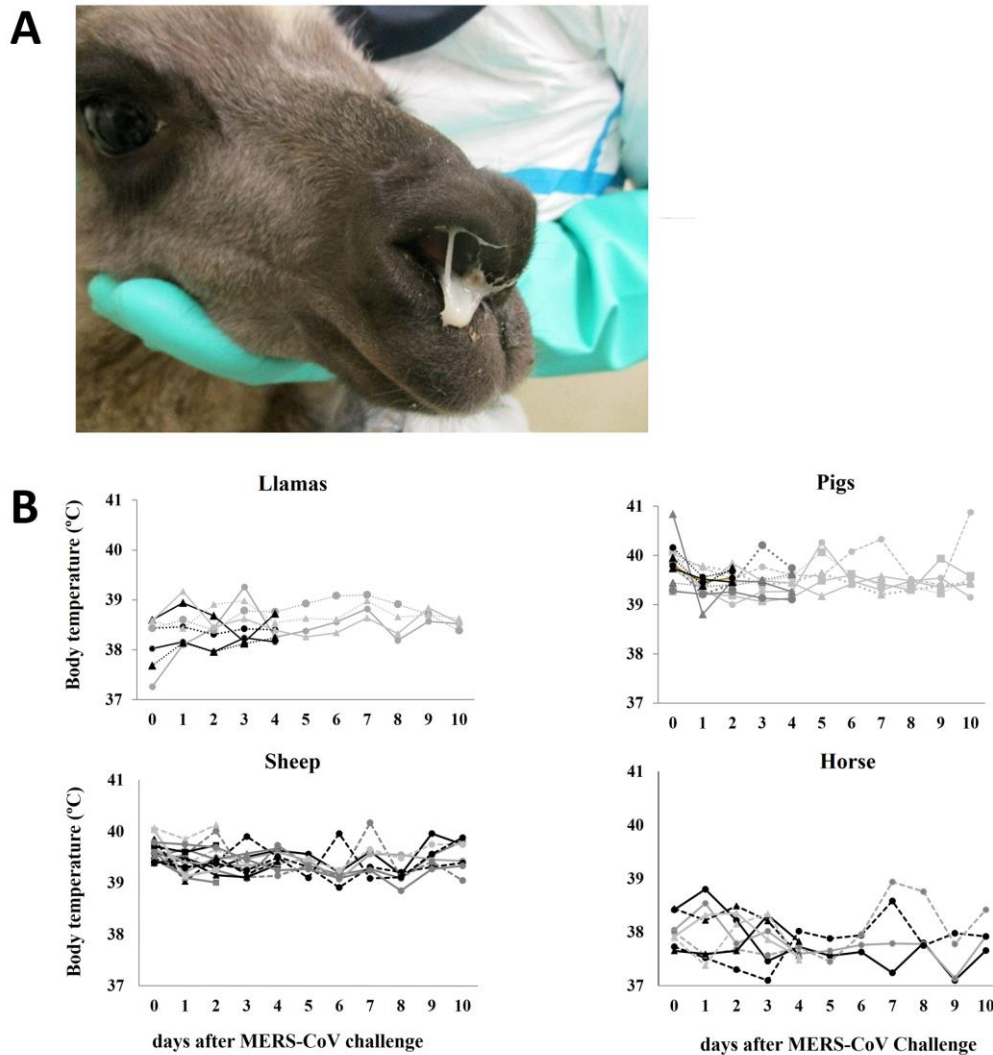
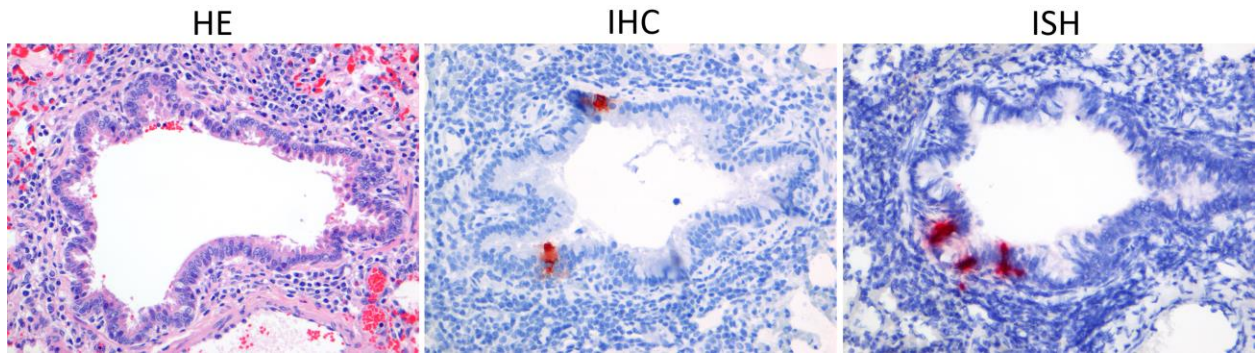


Livestock Susceptibility to Infection with Middle East Respiratory Syndrome Coronavirus

Technical Appendix



Technical Appendix Figure 1. Clinical signs after MERS-CoV inoculation in llamas, pigs, horses, and sheep. A) Presence of mucus excretion in a llama at 4 days postinoculation. B) Rectal body temperatures in llamas, pigs, sheep, and horses at different times postinoculation.



Technical Appendix Figure 2. Histology, IHC, and ISH in the lung of a sheep 2 days postinoculation with MERS-CoV. Few bronchiolar cells stained positive for MERS-CoV antigen in 1 out of 4 sheep (HE, IHC, ISH magnification $\times 200$).