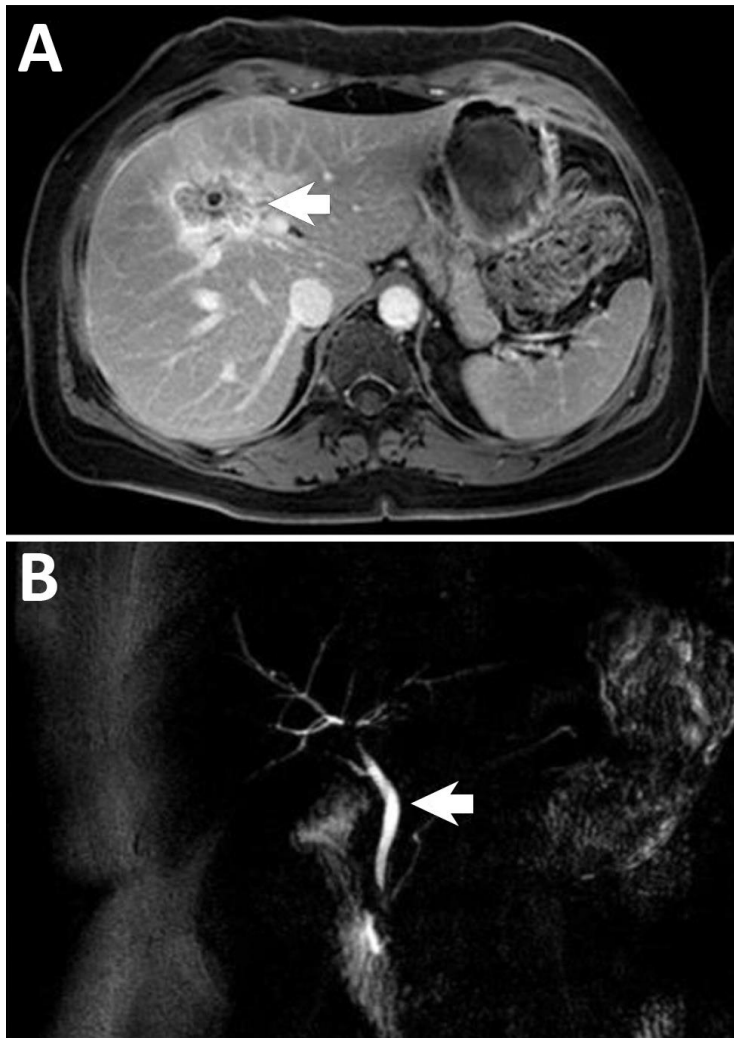


Hepatic Brucellosis Diagnosis and Long-term Treatment, France

Appendix



Appendix Figure. Computed tomography image showing a liver abscess in a patient with hepatic brucellosis at the time of diagnosis. Arrow indicates a hypodense lesion with a peripheral enhancement of the density and a central calcification. B) Computed tomography image of the liver of a patient with hepatic brucellosis after a 2-month treatment with doxycycline plus rifampin. Arrow indicates thrombosis of the median hepatic vein and infiltration of the gallbladder.

