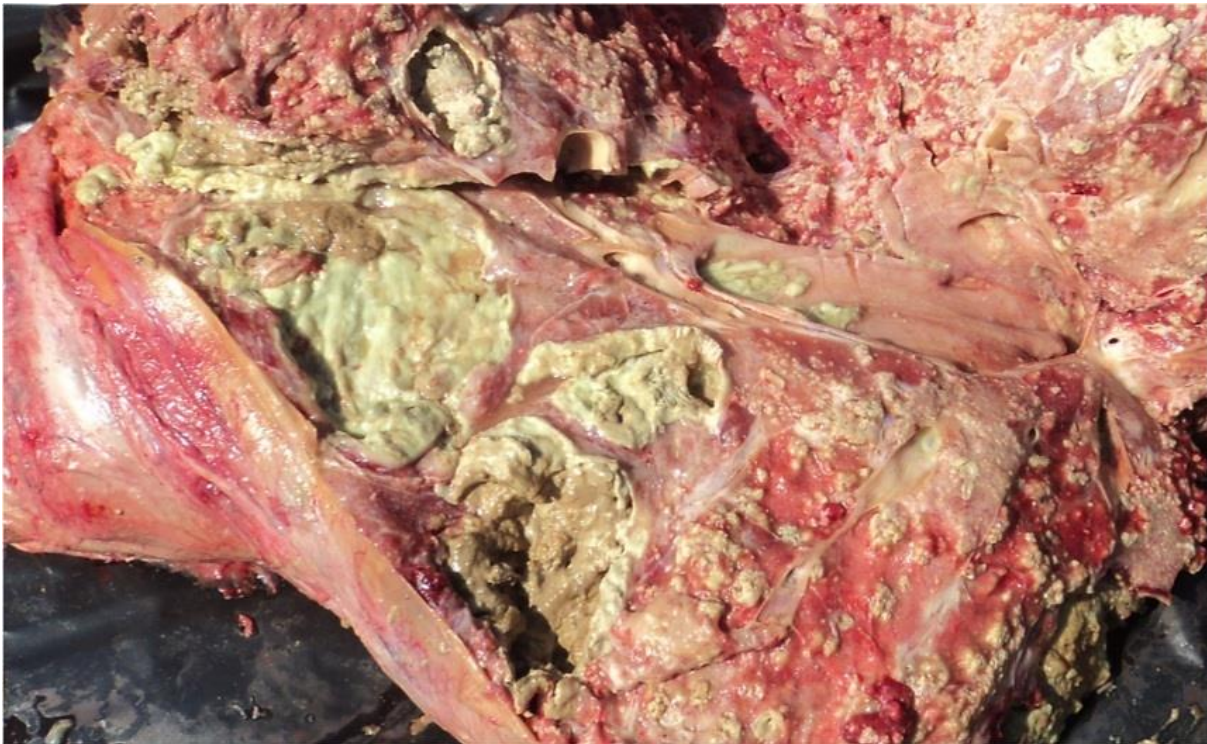
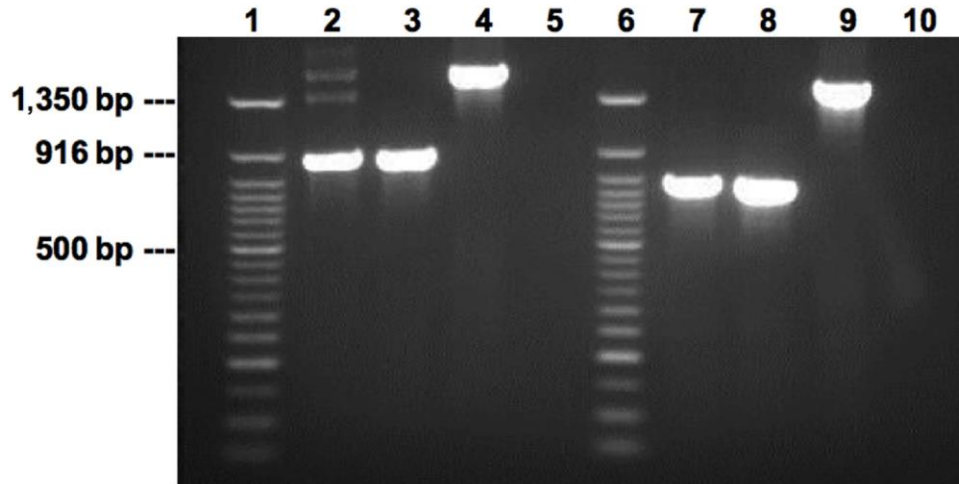


# Mixed *Mycobacterium tuberculosis* Lineage Infection in 2 Elephants, Nepal

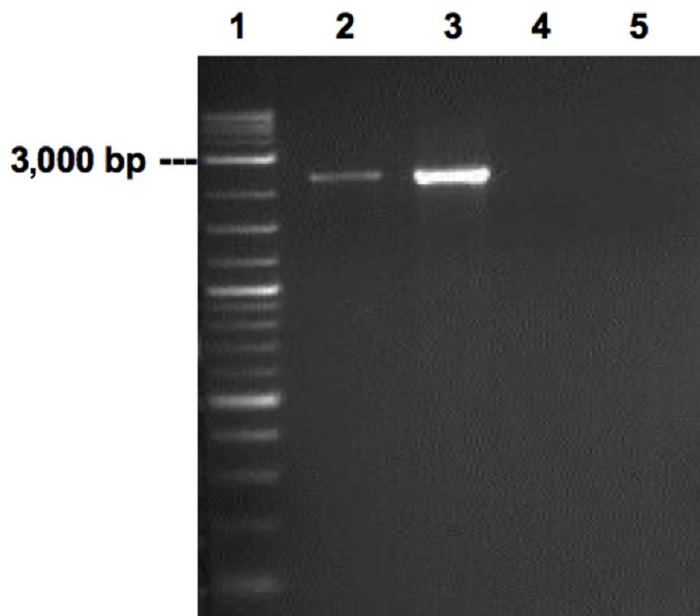
## Appendix



**Appendix Figure 1.** Granulomatous tuberculosis lesion with caseous mass in lungs of Elephant A.



**Appendix Figure 2.** Large Sequence Polymorphism (LSP) results of Elephant A isolate. Gel electrophoresis was run in isolate A using primers for Indo-oceanic lineage (lineage 1) and East-African-Indian lineage (lineage 3). Lanes: 1, 50bp DNA ladder; 2, Elephant A isolate; 3, positive control for Indo-Oceanic lineage; 4, H37Rv (Euro-American lineage, lineage 4); 5, negative control; 6, 50bp DNA ladder; 7, elephant sample; 8, positive control for East-African-Indian lineage; 9, H37Rv; 10, negative control.



**Appendix Figure 3.** Large Sequence Polymorphism (LSP) results of Elephant B isolate. Gel electrophoresis was run in isolate B using primers for East-Asian-Beijing (lineage 2). Lanes: 1, 2-log DNA ladder; 2, Elephant B isolate; 3, positive control for East-Asian-Beijing; 4, BCG; 5, negative control.