

rabies-endemic countries, physicians should emphasize the high likelihood of transmission of rabies virus after mucosal exposure and try to persuade persons at risk to receive postexposure prophylaxis.

About the Author

Dr. Zhao is a chief clinician specializing in the diagnosis and treatment of infectious diseases at the Department of Infectious Diseases, Second Hospital of Nanjing. Her research interests include viral hepatitis and other viral diseases.

References

1. Etheart MD, Kligerman M, Augustin PD, Blanton JD, Monroe B, Fleurinord L, et al. Effect of counselling on health-care-seeking behaviours and rabies vaccination adherence after dog bites in Haiti, 2014–15: a retrospective follow-up survey. *Lancet Glob Health*. 2017;5:e1017–25. [http://dx.doi.org/10.1016/S2214-109X\(17\)30321-2](http://dx.doi.org/10.1016/S2214-109X(17)30321-2)
2. Kan VL, Joyce P, Benator D, Agnes K, Gill J, Irmeler M, et al. Risk assessment for healthcare workers after a sentinel case of rabies and review of the literature. *Clin Infect Dis*. 2015;60:341–8. <http://dx.doi.org/10.1093/cid/ciu850>
3. Srinivasan A, Burton EC, Kuehnert MJ, Rupprecht C, Sutker WL, Ksiazek TG, et al.; Rabies in Transplant Recipients Investigation Team. Transmission of rabies virus from an organ donor to four transplant recipients. *N Engl J Med*. 2005;352:1103–11. <http://dx.doi.org/10.1056/NEJMoa043018>
4. Vora NM, Basavaraju SV, Feldman KA, Paddock CD, Orciari L, Gitterman S, et al.; Transplant-Associated Rabies Virus Transmission Investigation Team. Raccoon rabies virus variant transmission through solid organ transplantation. *JAMA*. 2013;310:398–407. <http://dx.doi.org/10.1001/jama.2013.7986>
5. Ross RS, Wolters B, Hoffmann B, Geue L, Viazov S, Grüner N, et al. Instructive even after a decade: complete results of initial virological diagnostics and re-evaluation of molecular data in the German rabies virus “outbreak” caused by transplantations. *Int J Med Microbiol*. 2015;305:636–43. <http://dx.doi.org/10.1016/j.ijmm.2015.08.013>
6. Zhou H, Zhu W, Zeng J, He J, Liu K, Li Y, et al. Probable rabies virus transmission through organ transplantation, China, 2015. *Emerg Infect Dis*. 2016;22:1348–52. <http://dx.doi.org/10.3201/eid2208.151993>
7. Chen S, Zhang H, Luo M, Chen J, Yao D, Chen F, et al. Rabies virus transmission in solid organ transplantation, China, 2015–2016. *Emerg Infect Dis*. 2017;23:1600–2. <http://dx.doi.org/10.3201/eid2309.161704>
8. Zhu JY, Pan J, Lu YQ. A case report on indirect transmission of human rabies. *J Zhejiang Univ Sci B*. 2015;16:969–70. <http://dx.doi.org/10.1631/jzus.B1500109>

Address for correspondence: Yi-Hua Zhou, Nanjing Drum Tower Hospital, Departments of Laboratory Medicine and Infectious Diseases, 321 Zhongshan Rd, Nanjing 210008, China; email: zgr03summer@126.com

Endemic Severe Fever with Thrombocytopenia Syndrome, Vietnam

Xuan Chuong Tran, Yeojun Yun, Le Van An, So-Hee Kim, Nguyen T. Phuong Thao, Phan Kim C. Man, Jeong Rae Yoo, Sang Taek Heo, Nam-Hyuk Cho, Keun Hwa Lee

Author affiliations: The Hue University Hospital and Hue University of Medicine and Pharmacy, Hue, Vietnam (X.C. Tran, L.V. An, N.T.P. Thao, P.K.C. Man); Ewha Womans University, Seoul, South Korea (Y. Yun); The Kyung Hee University, Seoul (S.-H. Kim); The Jeju National University College of Medicine, Jeju, South Korea (J.R. Yoo, S.T. Heo, K.H. Lee); Seoul National University College of Medicine, Seoul (N.-H. Cho)

DOI: <https://doi.org/10.3201/eid2505.181463>

Severe fever with thrombocytopenia syndrome (SFTS), a tickborne viral disease, has been identified in China, South Korea, and Japan since 2009. We found retrospective evidence of SFTS virus (SFTSV) infection in Vietnam, which suggests that SFTSV infections also occur in Vietnam, where the virus has not been known to be endemic.

Severe fever with thrombocytopenia syndrome virus (SFTSV) is a tickborne virus (genus *Phlebovirus*, family *Phenuiviridae*) that can cause a mild to severe febrile illness similar to hemorrhagic fever (1). Phleboviruses have been found in the Americas, Asia, Africa, and the Mediterranean region. For example, Heartland virus (HRTV), another tickborne phlebovirus, was identified in northwestern Missouri, USA, in 2009 (2). Malsoor virus, a new bat phlebovirus closely related to SFTSV and HRTV, was identified in western India, and a phlebovirus similar to SFTSV and HRTV was isolated from ticks in Australia (3,4).

Severe fever with thrombocytopenia syndrome (SFTS) illness was first confirmed in China in 2009. It was retrospectively identified in South Korea in 2010 and the western regions of Japan in 2013 (1,5,6). SFTS is characterized by acute high fever, thrombocytopenia, leukopenia, elevated serum hepatic enzymes, gastrointestinal symptoms, and multiorgan failure and has a death rate of 16.2%–30% (1,6,7). Atypical signs and symptoms and asymptomatic infections also have been identified (5,8). Most SFTSV infections occur through *Haemaphysalis longicornis* ticks, although SFTSV transmission can also occur through close contact with an infected patient (8).

To investigate evidence of SFTSV infections in Vietnam, we collected serum samples from 80 patients with acute febrile illnesses admitted to Hue University Hospital (Hue, Vietnam)

during October 1, 2017–March 31, 2018. The Institutional Review Board of Hue University Hospital approved the study.

For the molecular diagnosis of SFTSV, we extracted RNA from stored patient serum using a QIAamp Viral RNA Mini Kit (QIAGEN, <https://www.qiagen.com>) and performed real-time reverse transcription PCR (rRT-PCR) to amplify the partial small (S) segment of the viral RNA from the stored serum and confirm SFTSV infection (9). rRT-PCR showed 2 positive results, from the stored serum of 2 patients with thrombocytopenia who had been seen at Hue University Hospital during 2017 and who had no history of travel to SFTSV-endemic countries, such as China, South Korea, and Japan. We also detected IgM in the serum of 1 of these patients (Appendix Table, <https://wwwnc.cdc.gov/EID/article/25/5/18-1463-App1.pdf>) (8).

On October 29, 2017, a 29-year-old woman (Hue 06-Vietnam-10-2017) was hospitalized at Hue University Hospital because of headache, vomiting, and gum bleeding. She lived in Hue City and was unaware of having received an insect bite. Her temperature was 38°C, and blood tests showed leukopenia (leukocyte count 1,900 cells/ μ L [reference 4,000–10,000 cells/ μ L]), thrombocytopenia (platelet count $125 \times 10^3/\mu$ L [reference 150–450 $\times 10^3/\mu$ L]), and a low hematocrit level (34.3% [reference 36%–44%]). The patient fully recovered without other complications after 5 days.

On November 2, 2017, a 27-year-old man (Hue 13-Vietnam-11-2017) was hospitalized at Hue University Hospital because of headache and fatigue. He had had dengue fever at 8 years of age. Blood tests showed thrombocytopenia (platelet count $14 \times 10^3/\mu$ L), normal leukocyte count (7,410 cells/ μ L), mildly elevated aspartate aminotransferase (84 IU/L [reference 8–38 IU/L]), elevated alanine aminotransferase (98 IU/L [reference 4–44 IU/L]), and mildly elevated hematocrit (47.6% [reference 36%–44%]). He fully recovered without other complications after 7 days.

We sequenced rRT-PCR products from the stored serum samples using a BigDye Terminator Cycle Sequencing kit (Applied Biosystems, <http://www.thermofisher.com>). We performed phylogenetic analysis of the partial S segment sequences with MEGA6 (<https://www.megasoftware.net>) and constructed phylogenetic trees using the maximum-likelihood method, which confirmed SFTSV infection (Appendix Figure).

We confirmed 2 SFTSV infections in Hue in 2017 by amplifying the partial S segment of the viral RNA in stored serum from patients with thrombocytopenia; elevated levels of serum hepatic enzymes, including aspartate aminotransferase and alanine aminotransferase; and gastrointestinal symptoms, such as vomiting. The signs and symptoms were milder than the major signs and symptoms of SFTS, which has a high death rate.

H. longicornis, *Amblyomma testudinarium*, and *Ixodes nipponensis* ticks are vectors of SFTSV, and *A. testudinarium* has been found in Vietnam. Migratory birds are known to be long-distance carriers of virus-bearing ticks (10). Therefore, virus-bearing *A. testudinarium* ticks and migratory birds may play a role in dispersing SFTSV to Vietnam (10).

This study expands the understanding of the distribution of SFTSV in Southeast Asia and suggests that SFTSV may have a much wider global distribution than previously thought. The 2 patients reported here had relatively mild illness, and 1 did not have leukopenia. Therefore, further epidemiologic and clinical research is needed to clarify the epidemiology, geographic distribution, and transmission dynamics of SFTSV in Vietnam and other areas of Southeast Asia. This subject deserves further discussion and might warrant changes in the background description of the disease (5,8).

Acknowledgments

We thank L. Bakkensen for providing comments on this paper.

This work was supported by the Bio & Medical Technology Development Program of the National Research Foundation (NRF), funded by the South Korean government (grant no. NRF-2016M3A9B6021161), and a grant from the Korean Health Technology R&D Project of the Ministry of Health and Welfare, South Korea (grant no. HI15C2891).

About the Author

Dr. Tran is a professor at the Department of Infectious Diseases, Hue University Hospital and Hue University of Medicine and Pharmacy, Hue, Vietnam. His research interest is infectious diseases.

References

1. Yu XJ, Liang MF, Zhang SY, Liu Y, Li JD, Sun YL, et al. Fever with thrombocytopenia associated with a novel bunyavirus in China. *N Engl J Med*. 2011;364:1523–32. <http://dx.doi.org/10.1056/NEJMoa1010095>
2. McMullan LK, Folk SM, Kelly AJ, MacNeil A, Goldsmith CS, Metcalfe MG, et al. A new phlebovirus associated with severe febrile illness in Missouri. *N Engl J Med*. 2012;367:834–41. <http://dx.doi.org/10.1056/NEJMoa1203378>
3. Mourya DT, Yadav PD, Basu A, Shete A, Patil DY, Zawar D, et al. Malsoor virus, a novel bat phlebovirus, is closely related to severe fever with thrombocytopenia syndrome virus and Heartland virus. *J Virol*. 2014;88:3605–9. <http://dx.doi.org/10.1128/JVI.02617-13>
4. Wang J, Selleck P, Yu M, Ha W, Rootes C, Gales R, et al. Novel phlebovirus with zoonotic potential isolated from ticks, Australia. *Emerg Infect Dis*. 2014;20:1040–3. <http://dx.doi.org/10.3201/eid2006.140003>
5. Kim YR, Yun Y, Bae SG, Park D, Kim S, Lee JM, et al. Severe fever with thrombocytopenia syndrome virus infection, South Korea, 2010. *Emerg Infect Dis*. 2018;24:2103–5. <http://dx.doi.org/10.3201/eid2411.170756>

6. Takahashi T, Maeda K, Suzuki T, Ishido A, Shigeoka T, Tominaga T, et al. The first identification and retrospective study of severe fever with thrombocytopenia syndrome in Japan. *J Infect Dis.* 2014;209:816–27. <http://dx.doi.org/10.1093/infdis/jit603>
7. Li H, Lu QB, Xing B, Zhang SF, Liu K, Du J, et al. Epidemiological and clinical features of laboratory-diagnosed severe fever with thrombocytopenia syndrome in China, 2011–17: a prospective observational study. *Lancet Infect Dis.* 2018;18:1127–37. [http://dx.doi.org/10.1016/S1473-3099\(18\)30293-7](http://dx.doi.org/10.1016/S1473-3099(18)30293-7)
8. Yoo JR, Heo ST, Park D, Kim H, Fukuma A, Fukushi S, et al. Family cluster analysis of severe fever with thrombocytopenia syndrome virus infection in Korea. *Am J Trop Med Hyg.* 2016;95:1351–7. <http://dx.doi.org/10.4269/ajtmh.16-0527>
9. Zhang YZ, He YW, Dai YA, Xiong Y, Zheng H, Zhou DJ, et al. Hemorrhagic fever caused by a novel bunyavirus in China: pathogenesis and correlates of fatal outcome. *Clin Infect Dis.* 2012;54:527–33. <http://dx.doi.org/10.1093/cid/cir804>
10. Yun Y, Heo ST, Kim G, Hewson R, Kim H, Park D, et al. Phylogenetic analysis of severe fever with thrombocytopenia syndrome virus in South Korea and migratory bird routes between China, South Korea, and Japan. *Am J Trop Med Hyg.* 2015; 93:468–74. <http://dx.doi.org/10.4269/ajtmh.15-0047>

Address for correspondence: Keun Hwa Lee, Jeju National University College of Medicine, Department of Microbiology and Immunology, 15, Aran 13-gil, Jeju 63241, South Korea; email: yomust7@jejunu.ac.kr

Mixed *Mycobacterium tuberculosis* Lineage Infection in 2 Elephants, Nepal

Sarad Paudel,¹ Chie Nakajima,¹ Susan K. Mikota, Kamal P. Gairhe, Bhagwan Maharjan, Suraj Subedi, Ajay Poudel, Mariko Sashika, Michito Shimozuru, Yasuhiko Suzuki, Toshio Tsubota

Author affiliations: Hokkaido University, Sapporo, Japan (S. Paudel, C. Nakajima, M. Sashika, M. Shimozuru, Y. Suzuki, T. Tsubota); Elephant Care International, Hohenwald, Tennessee, USA (S.K. Mikota); Department of National Parks and Wildlife Conservation, Kathmandu, Nepal (K.P. Gairhe); German Nepal Tuberculosis Project, Kathmandu (B. Maharjan); National Trust for Nature Conservation, Lalitpur, Nepal (S. Subedi); Chitwan Medical College, Chitwan, Nepal (A. Poudel)

DOI: <https://doi.org/10.3201/eid2505.181898>

Tuberculosis in elephants is primarily caused by *Mycobacterium tuberculosis*. We identified mixed *M. tuberculosis* lineage infection in 2 captive elephants in Nepal by using spoligotyping and large sequence polymorphism. One elephant was infected with Indo-Oceanic and East African–Indian (CAS-Delhi) lineages; the other was infected with Indo-Oceanic and East Asian (Beijing) lineages.

Mycobacterium tuberculosis is a primary cause of tuberculosis (TB) in elephants (1). Culture of trunk wash samples is regarded as the standard method for the diagnosis of TB in elephants; however, this method has many limitations (2). We previously reported TB in 3 elephants in Nepal that was caused by *M. tuberculosis* of Indo-Oceanic lineage (3). Here, we report on mixed *M. tuberculosis* lineage infection in 2 captive elephants from Chitwan National Park (CNP) in Nepal.

Elephant A was a female elephant ≈65–70 years old. She had been in retirement for 3 years before she died in February 2013. We observed TB-like lesions in the lungs postmortem (Appendix Figure 1, <https://wwwnc.cdc.gov/EID/article/25/5/18-1898-App1.pdf>). Elephant B was a 32-year-old male. His body condition had substantially deteriorated for several months before he died. We found extensive TB-like lesions in the lungs at postmortem.

We performed the DPP VetTB Assay (Chembio Inc., <http://chembio.com>), a serologic test, on the postmortem lung fluid (an off-label use) of elephant A and the serum of elephant B; results were reactive in both cases, indicating the presence of antibodies to TB. We processed the suspected lung lesions according to standard guidelines (4) and performed culture by using Löwenstein–Jensen media.

We performed genetic analyses on the 2 *M. tuberculosis* isolates by using spoligotyping and large-sequence polymorphism (LSP) as described previously (5). We amplified the direct-repeat region with a primer pair and hybridized the PCR products to a set of 43 oligonucleotide probes corresponding to each spacer covalently bound to the membrane. We identified the spoligo-international type by comparing spoligotypes with the international spoligotyping database (SpolDB4) (6). We performed LSP on the isolates by using specific primers for respective lineages, as described previously (7).

We identified the elephant isolates as a mixture of 2 strains based on uneven spoligotyping color development (suggesting mixture) and LSP detection PCR results (2 bands were observed). The spoligotyping results showed that the elephant A isolate had a new spoligotype that was not found in the international spoligotyping database. The elephant B isolate belonged to the Indo-Oceanic lineage (East African–Indian 5 spoligo-international type 1365) (Table). The prevalence of the Indo-Oceanic lineage among human TB patients in Nepal is only 11.5% (8). The drug

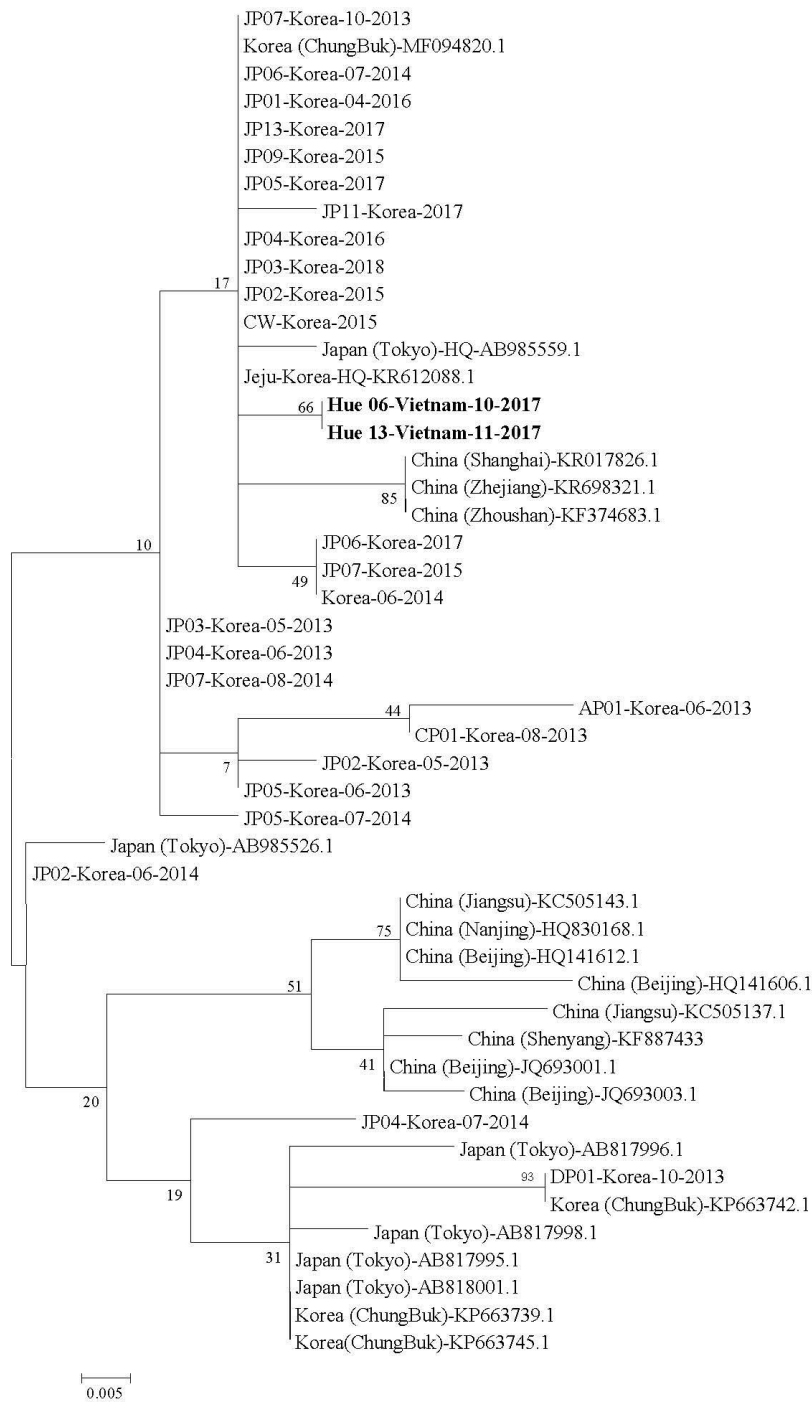
¹These first authors contributed equally to this article.

Endemic Severe Fever with Thrombocytopenia Syndrome, Vietnam

Appendix

Appendix Table. Detection of severe fever with thrombocytopenia syndrome virus antibody, Vietnam

No	Patient	IgM-capture ELISA, optical density	IgG-capture ELISA, optical density
1	Hue 06-Vietnam-10-2017	+3.48	-1.69
2	Hue 13-Vietnam-11-2017	+/-1.05	-1.35
3	Positive control	1.73	2.60
4	Negative control	0.23	0.14



Appendix Figure. Phylogenetic tree constructed based on partial small (S) segment sequences of severe fever with thrombocytopenia syndrome virus. The tree was constructed using the maximum-likelihood method with MEGA 6. The partial S sequences from stored serum collected in Vietnam in 2017 and analyzed in this study are shown in bold (Hue-06-Vietnam-10–2017 and Hue-13-Vietnam-11–2017). The partial S sequence data of the viruses identified in China, South Korea, and Japan were obtained from NCBI/BLAST (<http://blast.ncbi.nlm.nih.gov/Blast.cgi>).