

were characterized as *stx2/stx2vh-a* by PCR-restriction fragment length polymorphism.

To our knowledge, this is the first HUS case in our country in which the source of infection was identified. No investigation was conducted to trace back the source of the ground beef. This study illustrates the importance of the surveillance of STEC infections and the usefulness of molecular subtyping techniques, such as PFGE and phage typing, to determine the relatedness of strains and assess epidemiologic associations.

The public should be made aware that hamburgers, even when prepared at home, can be a source of infection. A primary strategy for preventing infection with *E. coli* O157:H7 is reducing risk behaviors through consumer education (10).

Acknowledgments

We thank Patricia Griffin for her review and helpful comments on earlier draft.

This work was supported by grants from Centers for Disease Control and Prevention (USA) and Fundación Alberto J. Roemmers (Argentina).

**Marta Rivas,* María Gracia Caletti,†
Isabel Chinen,* Stella Maris Refi,‡
Carlos Daniel Roldán,†
Germán Chillemi,*
Graciela Fiorilli,† Alicia Bertolotti,‡
Lorena Aguerre,*
and Sergio Sosa Estani§**

*Instituto Nacional de Enfermedades Infecciosas-ANLIS "Dr. Carlos G. Malbrán," Buenos Aires, Argentina.; †Hospital Nacional de Pediatría "Prof. Dr. Juan Garrahan," Buenos Aires, Argentina; ‡Laboratorio Central de Salud Pública, La Plata, Argentina; and §Centro Nacional de Diagnóstico e Investigación en Endemio-epidemias-ANLIS "Dr. Carlos G. Malbrán," Buenos Aires, Argentina

References

1. Comité de Nefrología de la Sociedad Argentina de Pediatría. Incidencia del síndrome urémico hemolítico (SUH) en la República Argentina. Arch Arg Pediatr 1995;93:409–11.
2. Gianantonio CA, Vitacco M, Mendilaharsu F, Ruddy A, Mendilaharsu J. The hemolytic-uremic syndrome. J Pediatr 1964;64:478–91.
3. Spizzirri FD, Rahman RC, Bibiloni N, Ruscaso JD, Amoreo OR. Childhood hemolytic uremic syndrome in Argentina: long-term follow-up and prognostic features. Pediatr Nephrol 1997;11:156–60.
4. Miliwebsky ES, Balbi L, Gomez D, Wainsztein R, Cueto Rúa M, Roldan C, et al. Síndrome urémico hemolítico en niños de Argentina: asociación con la infección por *Escherichia coli* productor de toxina Shiga. Bioq Patol Clin 1999;63:113–21.
5. Griffin PM, Tauxe R. The epidemiology of infections caused by *Escherichia coli* O157:H7, other enterohemorrhagic *E. coli* and the associated hemolytic uremic syndrome. Epidemiol Rev 1991;13:60–98.
6. Pollard DR, Johnson WM, Lior H, Tyler SD, Rozee KR. Rapid and specific detection of verotoxin genes in *Escherichia coli* by the polymerase chain reaction. J Clin Microbiol 1990;28:540–5.
7. Paton A, Paton J. Detection and characterization of Shiga toxinigenic *Escherichia coli* by using multiplex PCR assays for *stx1*, *stx2*, *eaeA*, enterohemorrhagic *E. coli hlyA*, *rfbO111*, and *rfbO157*. J Clin Microbiol 1998;36:598–602.
8. Heuvelink AE, Zwartkruis-Nahuis JTM, De Boer E. Evaluation of media and test kits for the detection and isolation of *Escherichia coli* O157 from minced beef. J Food Prot 1997;60:817–24.
9. Chinen I, Tanaro JD, Miliwebsky E, Lound LH, Chillemi G, Ledri S, et al. Isolation and characterization of *Escherichia coli* O157:H7 from retail meats in Argentina. J Food Prot 2001;64:1346–51.
10. Griffin PM, Mead P, Sivapalasingam S. *Escherichia coli* O157:H7 and other enterohemorrhagic *Escherichia coli*. In: Blaser MJ, Smith PD, Ravdin JI, Greenberg HB, Guerrant RL, editors. Infections of the gastrointestinal tract, 2nd edition. Philadelphia: Lippincott Williams and Wilkins; 2002. p. 627–42.

Address for correspondence: Marta Rivas, Servicio Fisiopatogenia, Instituto Nacional de Enfermedades Infecciosas-ANLIS "Dr. Carlos G. Malbrán," Av. Vélez Sarsfield 563 (1281), Buenos Aires, Argentina; fax: +54-11-4303-1801; email: mrvivas@anlis.gov.ar

Q Fever in Thailand

To the Editor: *Coxiella burnetii*, a strict intracellular bacterium, is the etiologic agent of Q fever, a worldwide zoonosis. Humans are infected by inhaling contaminated aerosols from amniotic fluid or placenta or handling contaminated wool (1). The bacterium is highly infectious by the aerosol route. Two forms of the disease are typical: acute and chronic. Acute Q fever is the primary infection and in specific hosts may become chronic (1,2). The major clinical manifestations of acute Q fever are pneumonia and hepatitis. Less common clinical manifestations are aseptic meningitis and/or encephalitis, pancreatitis, lymphadenopathy that mimics lymphoma, erythema nodosum, bone marrow necrosis, hemolytic anemia, and splenic rupture (2). The main clinical manifestation of the chronic form is culture-negative endocarditis, but infection of vascular grafts or aneurysms, hepatitis, osteomyelitis, and prolonged fever have also been described (1,2). Fluoroquinolones, co-trimoxazole, and doxycycline are active against *C. burnetii* in vitro, and ceftriaxone has been shown to have a bacteriostatic effect and could be effective in the phagolysosome of *C. burnetii*-infected cells (3). However, the treatment of choice for Q fever is doxycycline.

The incidence of this disease is largely unknown, especially in Asia. Q fever has been reported from Japan and China (1). Seroepidemiologic surveys have shown that subclinical infection is common worldwide. Large outbreaks of Q fever have also been reported in many countries in Europe (4). A case series of acute Q fever was diagnosed in a prospective study in patients with acute febrile illness who were admitted to four hospitals in northeastern Thailand: Udonthani Hospital, Udonthani Province; Maharat Nakhon Ratchasima Hospital, Nakhonratchasima Pro-

vince; Loei Hospital, Loei Province; and Banmai Chaiyapod Hospital, Bureerum Province. Two serum samples were taken from these patients, on admission and at a 2- to 4-week outpatient follow-up visit, and stored at -20°C until serologic tests were performed at the Faculty of Medicine Siriraj Hospital, Mahidol University, and the National Research Institute of Health, Public Health Ministry of Thailand. All serum samples were tested for the serologic diagnosis of leptospirosis, scrub typhus, murine typhus, and dengue infection as previously described (5,6). After these serologic tests were performed, serum samples from patients with unknown diagnosis were sent for the serologic test for Q fever at Unité des Rickettsies, Faculté de Médecine, Marseille, France. The microimmunofluorescent antibody test, using a panel antigen of *C. burnetii*, *Rickettsial honei*, *R. helvetica*, *R. japonica*, *R. felis*, *R. typhi*, *Bartonella henselae*, *B. quintana*, *Anaplasma phagocytophila*, and *Orientia tsutsugamushi*, was used as described previously (6).

A total of 1,171 serum specimens from 678 patients were tested for Q fever. Nine patients (1.3%, eight male and one female) fulfilled the diagnosis of acute Q fever. The median age was 42 (range 15–62) years. All patients were rice farmers, and their farm animals were chicken and cattle. The median duration of fever was 3 (range 1–7) days before admission into the hospital. When initially seen,

all patients had acute febrile illness, headache, and generalized myalgia (i.e., a flulike syndrome). Clinical manifestations of acute Q fever in these patients ranged from this flulike syndrome (three patients), pneumonitis (one patient), hepatitis (two patients), pneumonitis and renal dysfunction (one patient), hepatitis and renal dysfunction (one patient), to severe myocarditis and acute renal failure (one patient). An epidemic of leptospirosis has been occurring in Thailand since 1996 (7). All patients in this study received a diagnosis of either leptospirosis or acute fever of undefined cause; therefore, empirical therapy, including penicillin G sodium, doxycycline, and cefotaxime or ceftriaxone, was administered. The patient with hepatic and renal dysfunction was treated with co-trimoxazole. The patient who had severe myocarditis and acute renal failure was treated with a penicillin G sodium and doxycycline combination. He also received a dopamine infusion and hemodialysis. The median duration between admission and a reduction of fever was 3 days (range 1–7) in this case series.

Results of several seroprevalence studies, using the complement fixation test, conducted in both humans and animals suggest that *C. burnetii* infection has been widespread in Thailand since 1966 (8). The prevalence in asymptomatic persons varies from 0.4% to 2.6% (9), and studies in domestic animals show that the highest prevalence of this infection occurs

in dogs (28.1%). The prevalence in goats, sheep, and cattle varies from 2.3% to 6.1% (9). However, this clinical case series of acute Q fever is the first diagnosed in this country. The disease was diagnosed in patients in four hospitals, situated in various parts of the northeastern region of Thailand. These data confirmed that Q fever is widespread in this country. The disease had been unrecognized previously because the specific serologic test was not widely available in Thailand.

A self-limited course was suspected in four cases in this series. However, severe cases, especially those with myocarditis, could be fatal. Therefore, doxycycline should be an empirical therapy for patients with acute febrile illness in areas where leptospirosis, scrub typhus, and acute Q fever are suspected, such as in rural Thailand. Further studies to investigate the epidemiology of Q fever in this country are needed.

Acknowledgement

This work was part of research supported by grants from Thailand Research Fund, Thailand.

Yupin Suputtamongkol,*
Jean-Marc Rolain,†
Kitti Losuwanarak,‡
Kanigar Niwatayakul,§
Chuanpit Suttinont,¶
Wirongrong Chierakul,*
Kriangsak Pimda,#
and Didier Raoult†

EMERGING INFECTIOUS DISEASES *online*

www.cdc.gov/eid

To receive tables of contents of new issues send an email to listserv@cdc.gov with subscribe eid-toc in the body of your message.

*Mahidol University, Bangkok, Thailand; †Faculté de Médecine, Marseille, France; ‡Banmai Chaiyapod Hospital, Bureerum Province, Thailand; §Maharat Nakhon Rtacha-sima Hospital, Nakornrachasema Province, Thailand; ¶Loei Hospital, Loei Province, Thailand; and #Udornthani Hospital, Udornthani Province, Thailand

References

- Maurin M, Raoult D. Q fever. *Clin Microbiol Rev* 1999;12:518–53.
- Raoult D, Tissot-Dupont H, Foucault C, Gouvernet J, Fournier PE, Bernit E, et al. Q fever 1985–1998, clinical and epidemiologic features of 1,383 infections. *Medicine* 2000;79:109–22.
- Torres H, Raoult D. In vitro activities of ceftriaxone and fusidic acid against 13 isolates of *Coxiella burnetii*, determined using the shell vial assay. *Antimicrob Agents Chemother* 1993;37:491–4.
- Dupuis G, Petite J, Peter O, Vouilloz M. An important outbreak of human Q fever in a Swiss Alpine valley. *Int J Epidemiol* 1987;16:282–7.
- Apassakij H, Silpajajakul K, Wansit R, Woodtayakorn J. Evaluation of the immunofluorescent antibody test for the diagnosis of human leptospirosis. *Am J Trop Med Hyg* 1995;52:340–3.
- La Scola B, Raoult D. Laboratory diagnosis of rickettsioses: current approaches to diagnosis of old and new rickettsial diseases. *J Clin Microbiol* 1997;35:2715–27.
- Tangkanakul W, Tharmaphornpil P, Plikaytis BD, Bragg S, Poonsuksombat D, Choomkasien P, et al. Risk factors associated with leptospirosis in northeastern Thailand, 1998. *Am J Trop Med Hyg* 2000;63:204–8.
- Sangkasuwan V, Pongpradit P. SEATO Medical research study on rickettsial diseases in Thailand. Annual research progress report, US Army–SEATO Medical Research Unit, Bangkok, Thailand: U.S. Army; 1967. p. 499–504.
- Sangkasuwan V, Pongpradit P. SEATO Medical research study on rickettsial diseases in Thailand. Annual research progress report, US Army–SEATO Medical Research Unit, Bangkok, Thailand: U.S. Army; 1968. p. 444–8.

Address for correspondence: Yupin Suputtamongkol, Department of Medicine, Faculty of Medicine at Siriraj Hospital, Mahidol University, Bangkok 10700, Thailand; fax: 66 2 412 5994; email: siysp@mahidol.ac.th

All material published in *Emerging Infectious Diseases* is in the public domain and may be used and reprinted without special permission; proper citation, however, is appreciated.

Correction, Vol. 9, No. 8

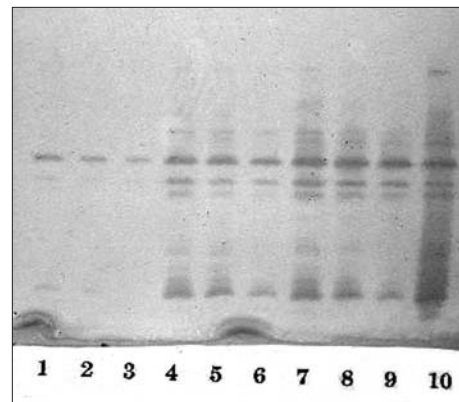
In "Emerging Pathogen of Wild Amphibians in Frogs (*Rana catesbeiana*) Farmed for International Trade," by Rolando Mazzoni et al., errors occurred in the figure legend on page 996.

The correct caption to the Figure appears below:

Figure. a and b, histopathologic findings from infected frogs. Characteristic sporangia (s) containing zoospores (z) are visible in the epidermis (asterisk, superficial epidermis; arrow, septum within an empty sporangium; bars, 10 µm). c, Skin smear from infected frog, stained with 1:1 cotton blue and 10% aqueous potassium hydroxide (aq KOH) (D, developing stages of *Batrachochytrium dendrobatidis*; arrow, septum within a sporangium; bar, 10 µm). d, Electron micrograph of an empty sporangium showing diagnostic septum (arrow) (bar, 2 µm).

Correction, Vol. 9, No. 8

In the article "NmcA Carbapenem-hydrolyzing Enzyme in *Enterobacter cloacae* in North America," by Sudha Pottumarthy et al., an error occurred the quality of the printing of Figure 3. A revised figure appears below. A color version is available from: URL: <http://www.cdc.gov/ncidod/EID/vol9no8/03-0096-G3.htm>



We regret any confusion this error may have caused.

Emerging Infectious Diseases Policy on Corrections

The *Emerging Infectious Diseases* journal wishes error-free articles. To that end, we

- 1) Make corrections as quickly as we become aware of errors
- 2) Publish corrections online and in print. Online, we correct the error in the article it occurred with a note that the article was corrected and the date of correction. In print, we prominently publish a full correction, printing all needed information, and provide the URL of the corrected online article for reprints.

For additional information on corrections, send e-mail to eideditor@cdc.gov.